

# Bowel Perforation in Preterm: Predictive Power of Bell Classification and Clinical Features

Melanie Kapapa<sup>1,\*</sup>, Janina Hahne<sup>2</sup>, Alexandre Serra<sup>1</sup>

<sup>1</sup>Division of Pediatric Surgery, Department of Surgery, University Medical Centre Ulm, Ulm, Germany

<sup>2</sup>Department of Pediatric and Adolescent Medicine, University Medical Centre Ulm, Ulm, Germany

## Email address:

[melanie.kapapa@uniklinik-ulm.de](mailto:melanie.kapapa@uniklinik-ulm.de) (Melanie Kapapa)

\*Corresponding author

## To cite this article:

Melanie Kapapa, Janina Hahne, Alexandre Serra. Bowel Perforation in Preterm: Predictive Power of Bell Classification and Clinical Features. *American Journal of Pediatrics*. Vol. 9, No. 4, 2023, pp. 210-216. doi: 10.11648/j.ajp.20230904.14

**Received:** October 2, 2023; **Accepted:** October 17, 2023; **Published:** November 11, 2023

**Abstract:** Objective: To evaluate outcome and survival rate we focused on the severity of necrotizing enterocolitis without (NEC) or with perforation (NECp) and spontaneous intestinal perforation (SIP) and their influence on clinical deterioration and surgical complications. Methods: Aim was to compare the clinical features, radiographic findings and outcome of SIP, NEC and NECp. Focus was on a potential risk profile and 76 preterm were included. Results: Symptoms started earlier in SIP ( $p < 0.001$ ). Systemic signs were led by body temperature instability ( $p = 0.014$ ), hypotension ( $p = 0.022$ ), manifested sepsis ( $p = 0.011$ ), septic shock ( $p = 0.010$ ) and disseminated intravascular coagulation ( $p = 0.021$ ). The Bell classification was suitable for staging NEC ( $p < 0.001$ ) and indication for laparotomy ( $p < 0.001$ ), but postinterventional 17% has to be upgraded to stage IIb ( $p < 0.001$ ). Abdominal distension ( $p = 0.003$ ) and -resistance ( $p = 0.033$ ) were significantly more often found in NEC, while bloody stool ( $p = 0.035$ ), oedematous abdominal wall ( $p = 0.044$ ) and abdominal skin discoloration ( $p < 0.001$ ) were typical for NECp or SIP, like an abdominal wall erythema ( $p = 0.049$ ) for NECp. Radiographically signs like pneumatizes intestinalis ( $p < 0.001$ ), bowel dilatation ( $p = 0.012$ ) and thickened intestinal walls ( $p < 0.001$ ) were less present in SIP, contrary to a pneumoperitoneum ( $p < 0.001$ ), but survival rate did not differ. Conclusion: BELL classification is suitable for assigning NEC, but the degree of severity was underestimated in 17% of preterm. Focus should be on sick preterm with a coagulation disorder/ DIC, after resuscitation, glucose utilization disorder, septic shock or manifested sepsis. Intubation or high frequency ventilation were additionally risking for NECp followed by higher mortality rate.

**Keywords:** Neonatology, Nec, Bell Classification, Survival, Outcome

## 1. Introduction

Spontaneous Intestinal Perforation (SIP) and Necrotizing Enterocolitis (NEC) affect mostly premature infants [1] with extremely low birth weight (2) and their etiology is mainly unknown [3]. In NEC preterm severe processes involving mostly all bowel loops could lead to a fulminant necrosis with multiple perforations (NECp), which were desperately feared because of a mortality rate up to 70% [2]. Differentiation between NEC and SIP is often not certainly possible, but essential to make a statement about prognosis of disease and clinical outcome [4]. In addition to a certain amount of experience, diagnosis of suspect preterm required good monitoring and careful observation. Abdominal

symptoms classified in BELL criteria are neither specific nor obligatory and the staging included 3 main and 6 sub-stages [5]. According to systemic and abdominal symptoms (for example gallic stomach contents, edematous abdomen, bloody stools and sepsis) as well as radiological signs (pneumoperitoneum) and laboratory findings (coagulation disorder, elevated inflammatory markers), which allows therapy optimization adapted to degree of manifestation in affected preterm. Basic conservative therapy included feeding tube for draining the gastric juice, nutritional restriction, pain therapy and antibiotic treatment. In case of clinical deterioration, further diagnostics were carried out and in instance of a proven bowel perforation, neonatologists and pediatric surgeons always face the same dilemma [6], indication for surgical treatment or wait and see? Surgical

options are based on intraoperative findings and discussed controversially [7] like Robinson *et al.* showed. From simple sewing of perforation area to resection of a longer intestinal section with anastomosis and/ or attachment of an artificial intestinal exit, everything is possible and like Loh *et al.* reported surgery rates of 30-60% are well known [8]. This circumstance leads to controversy [9], as the cause may be, among other things, that the surgically treated premature infants are simply sicker and that this already worsens the clinical outcome. The BELL criteria should help to dedicate decision of surgical treatment to preterm in accordance to stage of disease and neontologists and surgeons' clinical experiences [6]. It was most important to make the right diagnosis quickly and to identify possible risk factors.

## 2. Methods

### 2.1. Design

The single-centre study was designed retrospective enrolling children with NEC, NECp and SIP in the tertiary hospital. Information was obtained through recorded in-hospital files, surgical reports and radiological imaging. Study period was 1 January 2004 to 31 December 2014. The local ethics committee approved this study (No. 13/15).

### 2.2. Inclusion Criteria

All preterm with NEC, NECp and SIP (< 37<sup>th</sup> pregnancy week) treated completely at the tertiary centre during study period were included.

### 2.3. Exclusion Criteria

Newborns  $\geq 37^{\text{th}}$  pregnancy week or < 37<sup>th</sup> pregnancy week with incomplete treatment at the tertiary centre as well as premature < 37<sup>th</sup> pregnancy week without clinical signs for NEC, NECp and SIP were excluded (n = 5).

### 2.4. Patients and Surveyed Subjects

The International Classification of Diseases (ICD-9 and ICD- 10) was used to identify all patients with the diagnostic code P07.3 for premature babies and specifically P77 for necrotizing enterocolitis and P78.0 for bowel perforation in the neonatal period. During the survey period for the study 26.396 deliveries occurred, therefrom 76 sick preterm (64.5% male and 35.5% female) represent our cohort.

### 2.5. Data Collection

Data were collected by using clinical files, radiologic study results and surgical reports, transferred to a database and analysed anonymously. Points of interest were beginning of symptoms and severity (Bell-Classification), medication postnatal, clinical-, laboratory- and radiologic findings, conservative or surgical treatment, diagnosis verified via surgery, duration of ICU and total hospital stay, survival at discharge.

## 2.6. Statistics

The recorded data were initially analysed with descriptive methods and clearly outlined. The mean, standard deviation, median and range were reported in the case of quantitative parameters, absolute and relative frequencies for the qualitative parameters. Exploratory tests between interesting subsets were selected based on the underlying parameters. When analysing frequencies, the Chi-Square Test and Fisher's Exact Test were used. The t-test and the Kruskal-Wallis test were used in the study of continuous variables. Given the size of the subsets, the t-test and non-parametric tests such as Mann-Whitney test, Wilcoxon and Kruskal-Wallis were performed in addition to ANOVA, including post-hoc testing. Ordered logistic regressions for univariate and multivariate group differences and analyses of covariance were performed. Significance was established as  $p \leq 0.05$ . All statistical tests were analysed using the IBM SPSS software, version 26 (IBM, Illinois, USA).

## 3. Results

### 3.1. Bell Criteria Stage

We could show that staging NEC and NECp in BELL classification was significantly solidly ( $p < 0.001$ ). We could place in stage IIb (pre-surgically diagnosed bowel perforation) 38.2% of NECp preterm (n = 29), but in 17.1% perforation was first detected intraoperatively (n = 13) and stage subsequently has to be upgraded to stage IIb afterwards (Figure 1).

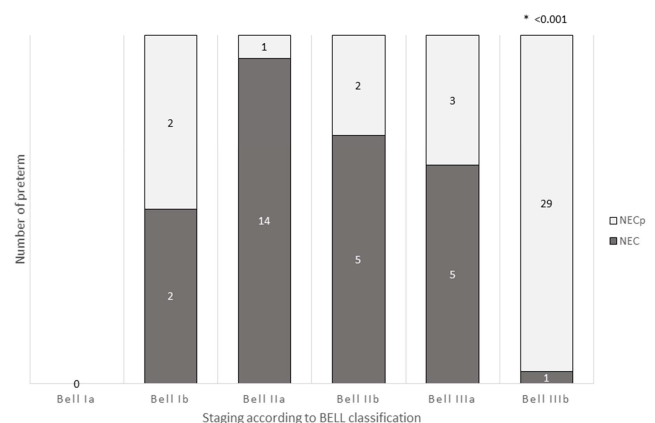


Figure 1. Staging of disease.

The Bell classification was suitable at a stage higher than IIa to assess the NEC disease ( $p < 0.001$ ) and surgical indication for laparotomy ( $p < 0.001$ ), while predicting a fatal outcome was close not significant ( $p = 0.051$ ). (Data not shown).

### 3.2. Systemic Signs

Several factors influenced NEC, NECp or SIP, but the beginning of symptoms was noticeable significantly different in preterm with SIP (8.6days), NEC (14.1days) or NECp

(23.7days) ( $p < 0.001$ ). (Figure 2)

In over 75% of preterm septic signs like marbled skin and capillary filling $>3$ sec. were found without significance. Systemic signs were led by body temperature instability ( $p = 0.014$ ), hypotension ( $p = 0.022$ ), manifested sepsis ( $p = 0.011$ ), septic shock ( $p = 0.010$ ) and disseminated intravascular coagulation ( $p = 0.021$ ) in NECp while comparing them vs. NEC and vs. SIP. In comparison of NEC/ NECp vs. SIP we found body temperature instability ( $p = 0.003$ ) and manifest sepsis ( $p = 0.047$ ) remaining significant. Hypotension was the only parameter which remains significant in comparing perforation vs. no perforation ( $p = 0.012$ ). (Table 1)

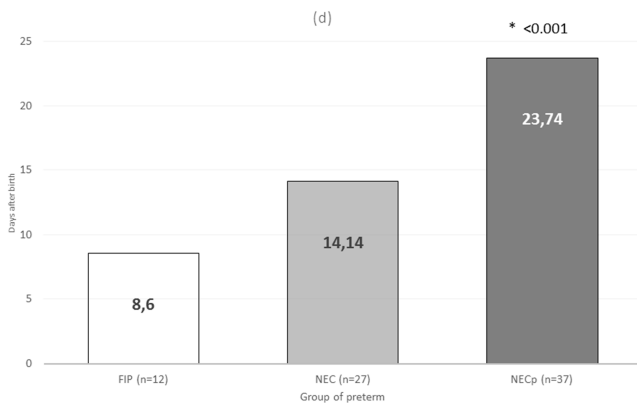


Figure 2. Beginning of clinical symptoms (d).

### 3.3. Gastrointestinal Signs

Different parameters of BELL classification for the gastrointestinal signs are differently pronounced in our NEC, NECp and SIP preterm. Signs like vomiting or stomach remnants showed no significant influence. Abdominal distension ( $p = 0.003$ ) and a resistance in the right lower abdomen ( $p = 0.033$ ) were significantly more often found in NEC vs. SIP preterm. Bloody stool ( $p = 0.035$ ), oedematous abdominal wall ( $p = 0.044$ ) and a green/ blue abdominal skin discoloration ( $p < 0.001$ ) were typical for preterm with bowel perforation (s) (SIP and NECp) as sign for progress of inflammation. An abdominal wall erythema ( $p = 0.049$ ) was significantly more often found in NECp preterm. While comparing NEC/NECp vs. SIP just abdominal distension ( $p = 0.011$ ) and resistance in the right lower abdomen ( $p = 0.027$ ) were significant. (Table 2)

### 3.4. Radiographic Signs

Radiological diagnosis is the mainstay for the definite detection of intestinal perforation, almost all sick preterm in our cohort have received an X-ray examination of the abdomen, typical radiological abnormalities were found in

97.3% of NECp children and in 100% of NEC and SIP children. Radiographic signs like pneumatosis intestinalis ( $p < 0.001$ ), dilated bowel loops ( $p = 0.012$ ) and thickened intestinal walls ( $p < 0.001$ ) were significantly less present in SIP and typically found in NEC preterm. A fully presentation with a pneumoperitoneum ( $p < 0.001$ ) was significantly for SIP preterm. First X-ray to diagnose an intestinal perforation was performed on average 1.3 hours after first symptoms in SIP preterm, while NECp preterm received X-ray later, after 5.6 hours, but the results were not significant. 31.6% of preterm obtained ultrasound scan as first imaging in case of a suspected bowel perforation. Comparing NEC/ NECp vs. SIP significance for pneumatosis intestinalis ( $p = 0.011$ ), thickened intestinal wall ( $p = 0.029$ ) and a pneumoperitoneum ( $p = 0.003$ ) was found, but only NECp preterm showed signs for ascites ( $p = 0.032$ ). Some of these results are still significant after testing perforation vs. no perforation like pneumatosis intestinalis ( $p < 0.001$ ), dilated bowel loops ( $p = 0.015$ ), and thickened intestinal wall ( $p < 0.001$ ) as well as pneumoperitoneum ( $p < 0.001$ ) with a positive result in a 2<sup>nd</sup> control abdominal X-ray ( $p = 0.046$ ). (Table 2)

Duration of NICU and total hospital stay, Preterm with NECp (99.5d) or FIP (62.1d) had a significant longer NICU stay ( $p = 0.001$ ) compared to NEC preterm (42.6d) and the duration of total hospital stay was also longest in NECp (154.2 d), followed by SIP (111.1 d) and shortest in NEC (96.5 d), but without significant differences. (Data not shown)

### 3.5. Discharge, Referral to Another Hospital, Survival Rate

Fifty-two-point six percent (52.6%,  $n = 40$ ) were discharged home, 27.6% were transferred to another hospital ( $n = 21$ ) and 19.7% of NEC or NECp preterm did not survive ( $n = 15$ ). The survival rate was highest in SIP newborn (100%) followed by 81.5% in NEC and was lowest in NECp preterm (73%). The survival rate was not significantly different ( $p = 0.121$ ) in contrast to the gender distribution ( $p = 0.039$ ), we found 26.5% of non-survivors were males ( $n = 13$ ) compared to 7.4% females ( $n = 2$ ). (Data not shown)

### 3.6. Linear Regression for Intestinal Perforation (Yes/No)

Regression analysis included factors which occur in case of an intestinal perforation in preterm, such as formula milk, abdominal discoloration, ascites thickened intestinal walls and pneumoperitoneum. (Table 3).

The multiple Regression analysis with cofactors showed further variables in relation to BELL criteria, such as preterm who died because of NEC/ NECp diagnosis, abdominal surgery and preterm who underwent resuscitation. (Table 3).

Table 1. Systemic signs and outcome.

Parameter	NEC (n = 27)	FIP (n = 12)	NECp (n = 37)	NEC vs. FIP vs. NECp p-value	Perforation vs. no perforation p-value	NEC/ NECp vs. FIP p-value
Septic signs	24 (88.9%)	11 (91.7%)	32 (88.2%)	0.081	1.000	1.000
marbled skin	18 (66.7%)	11 (91.7%)	28 (75.7%)	0.248	0.271	0.274

Parameter	NEC (n = 27)	FIP (n = 12)	NECp (n = 37)	NEC vs. FIP vs. NECp p-value	Perforation vs. no perforation p-value	NEC/ NECp vs. FIP p-value
capillary filling >3s	5 (18.5%)	0 (0%)	7 (18.9%)	0.263	0.745	0.195
body temperature instability	11 (40.7%)	0 (0%)	17 (45.9%)	0.014	0.627	0.003
tachycardia	7 (25.9%)	2 (16.7%)	15 (31.6%)	0.222	0.607	0.319
hypotension	13 (48.1%)	8 (66.7%)	30 (81.1%)	0.022	0.012	1.000
Manifest sepsis	7 (25.9%)	1 (8.3%)	19 (51.4%)	0.011	0.221	0.047
Septic shock	3 (11.1%)	0 (0%)	13 (35.1%)	0.010	0.148	0.060
Disseminated intravascular coagulation (DIC)	4 (14.8%)	1 (8.3%)	15 (40.5%)	0.021	0.109	0.166
Discharge/ Transfer (external hospital)	22 (81.5%)	12 (100%)	27 (73%)	0.271		
Death in hospital	5 (18.5%)	0 (0%)	10 (27.0%)	0.121	1.000	0.109

Table 2. Gastrointestinal and radiologic signs according to BELL criteria.

BELL- Criteria	NEC (n = 27; %)	FIP (n = 12; %)	NECp (n = 37; %)	NEC vs. FIP vs. NECp p-value	Perforation vs. no perforation p-value	NEC/ NECp vs. FIP p-value
Gastrointestinal signs	27 (100%)	11 (91.7%)	35 (94.6%)	0.382		
Gallic stomach remnant	2 (7.4%)	4 (33.3%)	5 (13.5%)	0.102	0.309	0.065
Abdominal distension	27 (100%)	9 (75.0%)	36 (97.3%)	0.003	0.291	0.011
Defence tension	26 (96.3%)	9 (75.0%)	34 (91.9%)	0.100	0.410	0.074
Bloody stool	12 (44.4%)	1 (8.3%)	8 (21.6%)	0.035	0.030	0.161
Oedematous abdominal wall	5 (18.5%)	5 (41.7%)	18 (48.6%)	0.044	0.024	0.706
Abdominal wall erythema	4 (14.8%)	2 (16.7%)	15 (40.5%)	0.049	0.106	0.492
Abdominal pain	20 (74.1%)	7 (58.3%)	29 (78.4%)	0.390	1.000	0.188
Resistance (right lower abdomen)	12 (44.4%)	2 (16.7%)	22 (59.5%)	0.033	0.812	0.027
Abdominal discoloration (green/blue)	2 (7.4%)	6 (50.0%)	23 (62.2%)	< 0.001	< 0.001	0.533
Radiographic signs in 1 <sup>st</sup> abdominal X-ray	27 (100%)	12 (100%)	36 (97.3%)	0.586		
Pneumatosis intestinalis	19 (70.4%)	1 (8.3%)	12 (32.4%)	< 0.001	< 0.001	0.011
Dilated bowel loops	20 (74.1%)	3 (25.0%)	18 (48.6%)	0.012	0.015	0.055
Thickened intestinal walls	14 (51.9%)	0 (0%)	6 (16.2%)	< 0.001	< 0.001	0.029
Portal venous gas detection	4 (14.8%)	1 (8.3%)	6 (16.2%)	0.795	1.000	1.000
Ascites	0 (0%)	0 (0%)	6 (16.2%)	0.032	0.083	0.581
Pneumoperitoneum	2 (7.4%)	11 (91.7%)	26 (70.3%)	< 0.001	< 0.001	0.003
2 <sup>nd</sup> abdominal X-ray	20 (74.1%)	12 (100%)	33 (89.2%)	0.071	0.046	0.195
3 <sup>rd</sup> X-ray + contrast agent	2 (7.4%)	1 (8.3%)	8 (21.6%)	0.231	0.455	0.455
Abdominal ultrasound	6 (22.2%)	3 (25.0%)	15 (40.5%)	0.258	0.211	0.434

Table 3. Linear Regression, relative risk Perforation (yes/no) and multiple regression.

Linear Regression Perforation (yes/no)				
Factor	OR	Significance	lower estimate	higher estimate
Preterm feeding with Formula Milk	0.426	0.054	-0.007	0.859
Abdominal distension	-0.246	0.078	-0.522	0.029
Abdominal discoloration (green/blue)	0.282	0.006	0.083	0.480
Thickened intestinal walls	-0.265	0.018	-0.482	-0.048
Ascites	0.669	0.001	0.297	1.041
Pneumoperitoneum	0.537	< 0.001	0.349	0.724
Multiple Regression with cofactors (BELL criteria)				
Factor	OR	Significance	lower estimate	higher estimate
Preterm non-survivors	0.262	0.000	3.620	8.847
Gender	-0.269	0.450	-0.429	0.953
NEC diagnosis	0.718	0.000	0.365	1.070
Infection	-0.207	0.440	-0.739	0.326
Resuscitation	-1.035	0.028	-1.955	-0.115
Surgery	-0.745	0.078	-1.576	0.086
Relative Risk for Perforation (yes/no)				
Factor	Relative risk	Significance	lower estimate	higher estimate
Coagulation disorder	4.645	0.014	1.224	17.623
Resuscitation	4.333	0.147	0.504	37.261
Glucose utilisation disorder	3.034	0.040	0.984	9.354
Septic shock	2.889	0.097	0.743	11.227
DIC	2.788	0.076	0.825	9.426
Manifest sepsis	1.970	0.147	0.702	5.531
Intubation	1.950	0.166	0.676	5.627
High frequency ventilation	1.128	0.548	0.342	3.723

### 3.7. Relative Risk for Intestinal Perforation 95% CI

The probabilities of variables for an intestinal perforation are listed in Table 3. The relative risk for an intestinal perforation is 4.645-fold higher for preterm with a coagulation disorder, 4.333-fold higher after resuscitation, 3.034-fold higher for preterm with a glucose utilisation disorder, 2.889-fold higher in septic shock preterm, 2.788-fold higher in those with DIC, 1.970-fold higher after manifested sepsis, 1.950-fold higher after intubation, 1.128-fold higher after high frequency ventilation (HFO).

## 4. Discussion

### 4.1. Bell Criteria Stage, Beginning of Symptoms, Systemic Signs

Rich et al. were able to show that the BELL criteria [10] are well suited to detect suspicious NEC preterm infants [11]. However, there is a not inconsiderable risk through strict classification into the categories, since they also include subjective parameters, that some of the preterm infants will be overlooked or sorted into a less severely affected group [12], which can lead to a delay in diagnosis. Premature babies with SIP are of course also classified via BELL parameter, since it is initially often not convinced whether it is a SIP or a NEC [11]. Through extracting missing parameters like capillary filling >3sec., body temperature instability and septic shock we could make it easier to classify an association to SIP in addition to the time of the first symptoms after birth [13]. Typical well-known factors for NEC are instability of body temperature [14], hypotension [15] or signs of progressing infection like DIC in a septic shock [16], the more of them that occur at the same time, the more likely it is that NEC or NECp will develop. Our findings are also supported by the fact that we were able to demonstrate that the relative risk for a bowel perforation in preterm increases 4.645-fold higher with a coagulation disorder, 4.333-fold higher after resuscitation, 3.034-fold higher with a glucose utilisation disorder, 2.889-fold higher in septic shock preterm, 2.788-fold higher with DIC, 1.970-fold higher after manifested sepsis and at least 1.950-fold higher after intubation.

### 4.2. Gastrointestinal Signs

The gastrointestinal signs within the BELL classification are divided into mild abnormalities such as increased gastric residuals via gastric tube and less present bowel sounds, but also clearly present abdominal pain and increasing abdominal distension [17]. Linder et al. support our analyses that abdominal distension [18] and bloody stool are typically signing for NEC and NECp, additionally oedematous abdominal wall or erythema [19], resistance in lower right abdomen [20], abdominal discoloration [21] were pathognomonic for NEC. The latter carry the risk that some clinicians may judge the pain as questionable and

subjectively perceive the distension as less pronounced. This would also explain a rate of 17% underdiagnosed preterm in our study with only intraoperatively proven perforated NEC, which was described before [12].

### 4.3. Radiographic Signs

Taking an abdominal X-ray to verify the presence of free abdominal air, as definite evidence of intestinal perforation, is always associated with risks of further complications in preterm infants. The child may have to be placed on the X-ray plate and every manipulation means stress, which in the worst case can lead to blood pressure problems or cerebral hemorrhages [22]. Abdominal X-ray is still the imaging process [23], which is most often used to confirm the diagnosis of NECp or SIP. De Bernardo et al. supported our results, but they also plead for, that ultrasound was more effective to detect in real time bowel destruction development [24]. The regular use of abdominal ultrasound has unfortunately not yet become widespread, as it has in our country. Several reasons could be causally: lack of examiners' expertise, lack of sonographic equipment or not yet adapted clinical standards in the diagnosis of NEC and/or SIP. Just 31.6% of our preterm received an abdominal ultrasound scan as first imaging in case of a suspected bowel perforation, this rate is too low and should be pushed up. Actual studies recommended [25] that suspected preterm profit of using ultrasound [26] to detect clinical deterioration much earlier like Esposito et al., who reviewed the emergent role of ultrasound [16, 27]. There is great potential for progress in this area and an improved rate of early detection of intra-abdominal abnormality for NEC and/or SIP if ultrasound would preferably be used.

### 4.4. Duration of NICU and Total Hospital Stays

To optimize surgical and clinical outcome selection of preterm and indication for surgery should be made restrictive and the possibility of other therapeutic options should be considered, because NECp preterm were longer hospitalized [28], as expected they were more severe ill with a 4-quadrants peritonitis prior and much more complications after necessary treatment in theatre [29].

### 4.5. Discharge, Referral to Another Hospital, Survival Rate

The outcome measured in the survival of premature babies does not reflect the paediatric expertise alone or only the paediatric surgical skills, it is rather an expression of an excellent cooperation which is characterised by trust in each other's skills and the will to subordinate one's own self-image to the well-being of the premature babies. It was well known that surgically treated NECp preterm died more often than conservatively treated NEC or SIP [30], but the 19.7% of non-survivors in our NECp group prove that cooperation between neonatologists on NICU and paediatric surgeons is already good, because much higher proportions of non-survivors are well known [31].

## 5. Conclusion

Every BELL parameter should be taken into context of the individual affected child, its gestational age, gender and other existing risk factors. Filtering out the warning signs like different beginning and severity of symptoms will improve preterm outcome with the combination of an early diagnosis through typical radiological signs, such as portal venous gas detection or a pneumoperitoneum. New established methods such as bedside ultrasound, should in the best-case lead to an acceleration of diagnosis, an increase in the survival rate and hopefully reduce the NICU stay. This means that sick premature receive the best possible conservative or, in an emergency, surgical treatment at the earliest possible stage. Technical progress will not be able to prevent NECp, but delaying the necessary surgical therapy should definitely be avoided via optimisation of the preoperative baseline conditions.

## Abbreviations an Acronyms

SIP: Spontaneous Intestinal Perforation

HFO: High Frequency Ventilation

ICD: International Classification of Diseases

NEC: Necrotizing Enterocolitis Without Perforation

NECp: Necrotizing Enterocolitis with Perforation

NICU: Neonatal Intensive Care Unit

## Statement of Financial Support

No financial assistance was received in support of this study.

## Ethics Approval and Consent Statement

Parents have given their written informed consent. All procedures performed in studies involving human participants were in accordance with the ethical standards of the institutional and/or national research committee and with the 1964 Helsinki declaration and its later amendments or comparable ethical standards. The study protocol has been approved by the research institute's committee on human research. The local ethics committee of the University Hospital Ulm approved this study (No. 13/15).

## Conflicts of Interest

The authors declare that they have no competing interests.

## Authors' Contributions

MK organized the study, performed the clinical examinations and was a major contributor in writing the manuscript. JH contacted the parents, organized the database and analysed the data. AS supervised the project and interpreted the patient data. All authors read and approved the final manuscript.

## References

- [1] Wadhawan R, Oh W, Vohr BR, Saha S, Das A, Bell EF, et al. Spontaneous intestinal perforation in extremely low birth weight infants: association with indometacin therapy and effects on neurodevelopmental outcomes at 18-22 months corrected age. *Archives of disease in childhood Fetal and neonatal edition*. 2013; 98(2): F127-32.
- [2] Stanford A, Upperman JS, Boyle P, Schall L, Ojimba JI, Ford HR. Long-term follow-up of patients with necrotizing enterocolitis. *Journal of pediatric surgery*. 2002; 37(7): 1048-50; discussion -50.
- [3] Neu J. Necrotizing enterocolitis: the mystery goes on. *Neonatology*. 2014; 106(4): 289-95.
- [4] Tiwari C, Sandlas G, Jayaswal S, Shah H. Spontaneous intestinal perforation in neonates. *Journal of neonatal surgery*. 2015; 4(2): 14.
- [5] Gephart SM, Gordon PV, Penn AH, Gregory KE, Swanson JR, Maheshwari A, et al. Changing the paradigm of defining, detecting, and diagnosing NEC: Perspectives on Bell's stages and biomarkers for NEC. *Seminars in pediatric surgery*. 2018; 27(1): 3-10.
- [6] Zani A, Eaton S, Puri P, Rintala R, Lukac M, Bagolan P, et al. International survey on the management of necrotizing enterocolitis. *European journal of pediatric surgery: official journal of Austrian Association of Pediatric Surgery [et al] = Zeitschrift fur Kinderchirurgie*. 2015; 25(1): 27-33.
- [7] Robinson JR, Rellinger EJ, Hatch LD, Weitkamp JH, Speck KE, Danko M, et al. Surgical necrotizing enterocolitis. *Seminars in perinatology*. 2017; 41(1): 70-9.
- [8] Loh M, Osborn DA, Lui K. Outcome of very premature infants with necrotising enterocolitis cared for in centres with or without on site surgical facilities. *Archives of disease in childhood Fetal and neonatal edition*. 2001; 85(2): F114-8.
- [9] Frost BL, Modi BP, Jaksic T, Caplan MS. New Medical and Surgical Insights Into Neonatal Necrotizing Enterocolitis: A Review. *JAMA pediatrics*. 2017; 171(1): 83-8.
- [10] Walsh MC, Kliegman RM. Necrotizing enterocolitis: treatment based on staging criteria. *Pediatric clinics of North America*. 1986; 33(1): 179-201.
- [11] Rich BS, Dolgin SE. Necrotizing Enterocolitis. *Pediatrics in review*. 2017; 38(12): 552-9.
- [12] Najaf TA, Vachharajani NA, Warner BW, Vachharajani AJ. Interval between clinical presentation of necrotizing enterocolitis and bowel perforation in neonates. *Pediatric surgery international*. 2010; 26(6): 607-9.
- [13] Bohler T, Bruder I, Ruef P, Arand J, Teufel M, Mohrmann M, et al. Necrotizing enterocolitis and focal intestinal perforation in neonatal intensive care units in the state of baden-wuerttemberg, Germany. *Pediatric reports*. 2014; 6(1): 5194.
- [14] McCall EM, Alderdice F, Halliday HL, Vohra S, Johnston L. Interventions to prevent hypothermia at birth in preterm and/or low birth weight infants. *The Cochrane database of systematic reviews*. 2018; 2: Cd004210.

- [15] Samuels N, van de Graaf RA, de Jonge RCJ, Reiss IKM, Vermeulen MJ. Risk factors for necrotizing enterocolitis in neonates: a systematic review of prognostic studies. *BMC pediatrics*. 2017; 17(1): 105.
- [16] Esposito F, Mamone R, Di Serafino M, Mercogliano C, Vitale V, Vallone G, et al. Diagnostic imaging features of necrotizing enterocolitis: a narrative review. *Quantitative imaging in medicine and surgery*. 2017; 7(3): 336-44.
- [17] Li YF, Lin HC, Torrazza RM, Parker L, Talaga E, Neu J. Gastric residual evaluation in preterm neonates: a useful monitoring technique or a hindrance? *Pediatrics and neonatology*. 2014; 55(5): 335-40.
- [18] Linder N, Hammel N, Hernandez A, Fridman E, Dlugy E, Herscovici T, et al. Intestinal perforation in very-low-birth-weight infants with necrotizing enterocolitis. *Journal of pediatric surgery*. 2013; 48(3): 562-7.
- [19] Gephart SM, Fleiner M, Kijewski A. The ConNEction Between Abdominal Signs and Necrotizing Enterocolitis in Infants 501 to 1500 g. *Advances in neonatal care: official journal of the National Association of Neonatal Nurses*. 2017; 17(1): 53-64.
- [20] Kosloske AM. Indications for operation in necrotizing enterocolitis revisited. *Journal of pediatric surgery*. 1994; 29(5): 663-6.
- [21] Khalak R, D'Angio C, Mathew B, Wang H, Guilford S, Thomas E, et al. Physical examination score predicts need for surgery in neonates with necrotizing enterocolitis. *Journal of perinatology: official journal of the California Perinatal Association*. 2018; 38(12): 1644-50.
- [22] Starr R, De Jesus O, Shah SD, Borger J. Periventricular Hemorrhage-Intraventricular Hemorrhage. *StatPearls*. Treasure Island (FL) 2021.
- [23] Ahle M, Ringertz HG, Rubesova E. The role of imaging in the management of necrotising enterocolitis: a multispecialist survey and a review of the literature. *European radiology*. 2018; 28(9): 3621-31.
- [24] De Bernardo G, Sordino D, De Chiara C, Riccitelli M, Esposito F, Giordano M, et al. Management of NEC: Surgical Treatment and Role of Traditional X-ray Versus Ultrasound Imaging, Experience of a Single Centre. *Current pediatric reviews*. 2019; 15(2): 125-30.
- [25] van Druten J, Khashu M, Chan SS, Sharif S, Abdalla H. Abdominal ultrasound should become part of standard care for early diagnosis and management of necrotising enterocolitis: a narrative review. *Archives of disease in childhood Fetal and neonatal edition*. 2019; 104(5): F551-f9.
- [26] Yikilmaz A, Hall NJ, Daneman A, Gerstle JT, Navarro OM, Moineddin R, et al. Prospective evaluation of the impact of sonography on the management and surgical intervention of neonates with necrotizing enterocolitis. *Pediatric surgery international*. 2014; 30(12): 1231-40.
- [27] Deeg KH. Sonographic and Doppler Sonographic Diagnosis of Necrotizing Enterocolitis in Preterm Infants and Newborns. *Ultraschall Med*. 2019; 40(3): 292-318.
- [28] Shah TA, Meinzen-Derr J, Gratton T, Steichen J, Donovan EF, Yoltan K, et al. Hospital and neurodevelopmental outcomes of extremely low-birth-weight infants with necrotizing enterocolitis and spontaneous intestinal perforation. *Journal of perinatology: official journal of the California Perinatal Association*. 2012; 32(7): 552-8.
- [29] Gephart SM, McGrath JM, Effken JA, Halpern MD. Necrotizing enterocolitis risk: state of the science. *Advances in neonatal care: official journal of the National Association of Neonatal Nurses*. 2012; 12(2): 77-87; quiz 8-9.
- [30] Fisher JG, Jones BA, Gutierrez IM, Hull MA, Kang KH, Kenny M, et al. Mortality associated with laparotomy-confirmed neonatal spontaneous intestinal perforation: a prospective 5-year multicenter analysis. *Journal of pediatric surgery*. 2014; 49(8): 1215-9.
- [31] Hansen ML, Juhl SM, Fonnest G, Greisen G. Surgical findings during exploratory laparotomy are closely related to mortality in premature infants with necrotising enterocolitis. *Acta paediatrica (Oslo, Norway: 1992)*. 2017; 106(3): 399-404.