



Case Report

Recurrent Acute Kidney Injury in a Child Due to CD46 Mutation Associated Hemolytic Uremic Syndrome: A Case Report and Review of Literature

Lipsa Priyadarshini, Subal Kumar Pradhan*

Division of Pediatric Nephrology, Sardar Vallabhbhai Patel Post Graduate Institute of Paediatrics & SCB Medical College, Cuttack, India

Email address:

drsubal@rediffmail.com (Subal Kumar Pradhan)

*Corresponding author

To cite this article:

Lipsa Priyadarshini, Subal Kumar Pradhan. Recurrent Acute Kidney Injury in a Child Due to CD46 Mutation Associated Hemolytic Uremic Syndrome: A Case Report and Review of Literature. *American Journal of Pediatrics*. Vol. 9, No. 3, 2023, pp. 122-125.
doi: 10.11648/j.ajp.20230903.14

Received: June 20, 2023; **Accepted:** July 7, 2023; **Published:** July 20, 2023

Abstract: Background: Atypical hemolytic uremic syndrome (aHUS) is a relatively rare disorder characterized by microangiopathic hemolytic anemia, thrombocytopenia, and renal dysfunction due to gene mutation of complement factors leading to dysregulated activation of the alternative complement pathway. Mutation of CD46 or membrane cofactor protein accounts for 5-20 percent of cases of atypical HUS. Clinical description: Here we report a 7-year-old boy with recurrent episodes of acute kidney injury and thrombocytopenia associated with diarrheal episode who was subsequently found to be having CD46 mutation. He was negative for anti-complement factor H (20AU/ml, ref 0-100 AU/ml). Renal ultrasonography showed normal kidney size with increased echogenicity. With a diagnosis of HUS with AKI and stage 1 hypertension, the patient was managed with amlodipine with monitoring of fluid and electrolyte status. The child underwent three sessions of hemodialysis. After one and half months of the episode, the patient got admitted for the third time with complaints of abdominal pain, hematuria, and oliguria. This episode was not associated with diarrhoea. His whole exome sequencing tested for mutation implicated in atypical HUS revealed a homozygous deletion (77bp) variant in Exon 14 of the CD46 gene. Patient was finally diagnosed with atypical HUS due to CD46 (MCP) mutation. Conclusion: HUS presenting in the context of a diarrhoeal episode should not always be assumed to be diarrhoea-associated HUS and in the recurrence of such episodes, screening for the genetic cause/complement mutation is crucial to establish underlying etiology and deciding therapeutic strategies.

Keywords: Atypical HUS, Acute Kidney Injury (AKI), Diarrhoea, Alternative Complement Pathway, CD 46 Mutation

1. Introduction

Hemolytic uremic syndrome (HUS), an important cause of acute kidney injury (AKI) in children is characterized by the clinical triad of microangiopathic haemolytic anemia (MAHA), thrombocytopenia, and renal involvement [1]. HUS occurs in three different clinical settings. Typical or post-diarrheal HUS, the most frequent form in children, is caused by infection with Shiga toxin-producing *Escherichia coli* (STEC), particularly serotype 0157:H7. Non-STEC associated HUS have a variety of triggers such as *Streptococcus pneumoniae*, various non-enteric infections,

viruses, drugs, malignancies, transplantation, or autoimmune disease. The less frequent form of the disease, in the absence of any identified preceding illness, is known as atypical HUS (aHUS). aHUS can occur at any age, from the neonatal period to adult age, with familial and sporadic cases [2, 3]. Complement pathway dysregulation accounts for the majority of the non-STEC cause of HUS [4]. So far, at least 70 complement genetic abnormalities have been reported in adults and children with aHUS [2]. Homozygous or heterozygous mutations of complement factor H (CFH), Complement factor I (CFI), complement factor B (CFB), complement C3, membrane cofactor protein (MCP, also known as CD46), thrombomodulin gene (THBD), or

diacylglycerol kinase- ϵ (DGKE) account for at least 50-60% of non STEC cases [2, 4, 5]. CD46 is a cofactor for complement factor I (CFI) in mediating C3b and C4b degradation [6]. CD46 mutation accounts for 5-20 percent of children with aHUS [7]. Treatment for aHUS in paediatric patients involves various therapeutic approaches, and eculizumab is one of the effective treatment options [8, 9]. It acts by inhibiting the terminal pathway of the complement system. Additionally, it can restore platelet counts to a normal range, enhance hemoglobin levels, and prevent the ongoing destruction of red blood cells. Though CD46 mutation experience natural recovery without any specific therapy including plasma exchange (PE), recently anti-complement therapy with eculizumab has been tried.

2. Case

A seven-year-old male child born out of non-consanguineous marriage presented with 5 days history of abdominal pain, loose motion, vomiting, hematuria, and decreased urination to our hospital. He was afebrile, without any breathing difficulty, jaundice, or rash. His weight (26 kg) and height (123 cm) were in the range of 50th – 85th centile. His blood pressure was 116/70 mmHg (95th - 95th +12 mm of Hg). He had pallor and mild facial puffiness. None of the family members had similar history.

He had a previous history of similar episodes at two and half years of age. At that time, the patient was admitted with acute gastroenteritis and AKI but a normal Total Platelet Count (TPC). Investigations showed Hb 11 gm/dl, with TPC 1.8 lac/mm³, raised serum urea 188mg/dl (reference 15-40 mg/dl), and serum creatinine 5.3 mg/dl (reference 0.7-1.5 mg/dl). The patient improved with conservative management and AKI got resolved.

After hospitalization, relevant investigations were sent which showed Hemoglobin - 7.9 gm/dl, total leucocyte count – 5470/ mm³, TPC 41000/mm³ (reference 1.5- 4 lakhs/mm³). Blood urea was 233.7 mg/dl (reference 15-40) and serum creatinine was 7.1 mg/dl (reference 0.7-1.5). Peripheral blood smear showing normocytic normochromic RBCs with schistocytes, fragmented cells, and helmet cells. The reticulocyte count was 4%. Urine examination showed plenty of RBC with 2+ albumin. Stool routine examination showed no RBC with 6-10 pus cells/HPF but no growth on culture. Malaria Parasite Immunochromatographic Test (MP ICT) and dengue NS1 antigen tests were negative. The Direct Coombs test and sickling tests were also found to be negative. Glucose-6-phosphate dehydrogenase (G-6-PD) activity was present. Lactate dehydrogenase (LDH) was raised by 2730 units/l (ref 313-618 units/l) and haptoglobin was low <40 mg/dl (ref 40-280 mg/dl) suggestive of intravascular hemolysis. His coagulation parameters were within normal range PT (prothrombin time) - 13 sec (ref 9.6-17.6), APTT (activated partial thromboplastin clotting time) – 32.3 sec (ref 21.5- 35.5), INR- 1.04. Liver function test showed ALT = 34 U/L (Ref 0-40), AST = 70 U/L (Ref 0-40), total serum bilirubin/ direct fraction (TSB D)- 1.3 mg/

dl (0.1) (Ref 0.2-1.2), Serum Albumin - 3 gm/dl (Ref 3.5-5.5). C3 was normal 111.6 mg/dl (ref 90-180 mg/dl) and ANA was negative 2.66 IU/ml (ref <20 IU/ml). He was negative for anti-complement factor H (20AU/ml, ref 0-100 AU/ml). Renal ultrasonography showed normal kidney size with increased echogenicity. With a diagnosis of HUS with AKI and stage 1 hypertension, the patient was managed with amlodipine with monitoring of fluid and electrolyte status. The child underwent three sessions of hemodialysis.

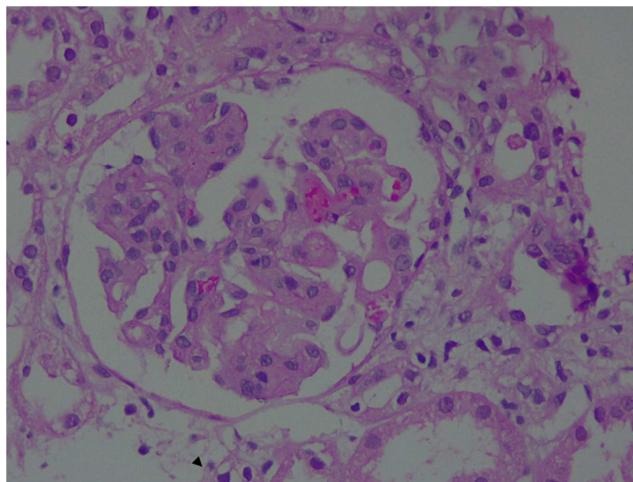


Figure 1. Light microscopy finding on renal biopsy showing mesangiolysis and deposition of thrombin (H & E).

Because of persisting oliguria and gross hematuria renal biopsy was planned. Renal histopathology study showed widespread ischemic glomerular changes including mesangiolysis, retracted tufts, wrinkled/pseudo-thickened capillary basement membrane, and RBC fragmentation with severe acute tubular injury (Figure 1). These features were suggestive of thrombotic microangiopathy with predominantly glomerular involvement.

Gradually AKI resolved. Serum urea (26.4mg/dl) and serum creatinine (0.79mg/dl) became normal after a week. Anemia and thrombocytopenia improved. Hematuria also subsided. The patient got discharged in hemodynamically stable condition in a normotensive state.

After one and half months of the episode, the patient got admitted for the third time with complaints of abdominal pain, hematuria, and oliguria. This episode was not associated with diarrhoea. He had pallor, no edema, and BP within normal range. Further evaluation showed Hb 9.7 gm/dl, TPC- 1.6 lakh/mm³, blood urea 158.9 mg/dl, and serum creatinine- 2.7 mg/dl. Urine analysis showed plenty of RBC/HPF. Having recurrent gross hematuria, flow cytometry for paroxysmal nocturnal hemoglobinuria (PNH) clone was sent to rule out PNH which came out to be negative. The patient improved gradually, hematuria and AKI resolved with conservative management.

Our patient had three similar episodes. The first episode was diarrhoea associated with AKI without anemia or thrombocytopenia, the second episode with typical features of diarrhoea associated HUS, and the third episode was not

associated with diarrhoea, there was no thrombocytopenia but the child had only anemia and AKI. Because of these-recurrent episodes of AKI, suspecting genetic/inherited causes of HUS, a genetic study was planned to identify the probable causal mutations.

His whole exome sequencing tested for mutation implicated in atypical HUS revealed a homozygous deletion (77bp) variant in Exon 14 of the CD46 gene (NM_002389.4). Patient was finally diagnosed with atypical HUS due to CD46 (MCP) mutation. He is on regular follow-up. Now he is asymptomatic and relapse-free for the last 3 months. He was normotensive, with normal haemoglobin, platelet count, renal function test, and LDH level during the last visit.

3. Discussion

Atypical HUS is a relatively rare disorder characterized by microangiopathic haemolytic anaemia, thrombocytopenia, and renal dysfunction due to gene mutation of complement factors leading to dysregulated activation of the alternative complement pathway. This results in the formation of the Membrane Attack Complex (MAC), renal endothelial damage, coagulation cascade activation, and thrombotic microangiopathy [10-12].

The exact frequency of CD46 mutation is not known, it accounts for almost 5-20% of all paediatric atypical HUS cases [7]. It usually affects younger children. The diagnosis of aHUS usually relies on - absolute or relative thrombocytopenia (platelet count below 150,000/mL or a 25% decline from the baseline), microangiopathic hemolytic anemia, and end-organ damage. Microbiologic tests for toxin-producing bacteria are negative [12]. High LDH and undetectable haptoglobin levels confirm intravascular hemolysis. TMA is histologically characterized by the thickening of arteriole and capillary walls, with prominent endothelial damage, accumulation of proteins and cell debris in subendothelial space, and fibrin and platelet-rich thrombi obstructing vessel lumina. TMA predominantly affects the renal microvasculature. Most of the children don't require plasma therapy. As CD46 is a transmembrane protein, plasma therapy usually does not provide additional benefits [2, 13, 15-17]. Although it has a relapsing course, few children with this mutation progress to end-stage renal disease (ESRD). It has a favorable outcome with a lower risk of recurrence in kidney allograft [2, 7, 13, 17].

Interestingly, the prognosis of aHUS varies according to genotype. The worst prognosis is in patients with CFH mutation and the best in patients with MCP mutation [17]. Reports mention zero mortality at the first episode in MCP-mutated children as compared to 20-30% mortality in CFH-mutated children. Besides, evolution to ESRD at the first episode was reported as high as 20-40% in survivors of CFH-mutated children whereas no ESRD has been reported in MCP-mutated children. At three to five years, approximately 75% of CFH-mutated patients and 50-60% of CFI-mutated patients had died or reached ESRD. While 38% of MCP-mutated children in the French pediatric cohort had

reached ESRD at 5 years follow-up after several relapses, only 6% of MCP-mutated patients in the Italian registry had developed ESRD at that stage, varying from 0% in children to 25% in adults [2, 15, 17].

In almost 70-80 percent of cases of complement-mediated HUS, an antecedent trigger event in the form of upper respiratory tract infection, diarrhoeal episode, and pregnancy is thought to play a role in complement activation [2, 12]. Our case highlights the importance of genetic testing for screening underlying complement defects in the recurrent presentation of diarrhoeal-associated HUS. Further diagnosing the genetic mutation in these children is important because of the implication for the further management of the disease, and detection in their siblings and parents.

4. Conclusion

In conclusion, HUS patient present in the context of a diarrhoeal episode should not always be assumed to be diarrhoea-associated HUS and in the recurrence of such episodes, screening for the genetic cause/complement mutation is crucial to establish underlying etiology and deciding therapeutic strategies. Currently, there is no proven therapy available for treating HUS patients with CD46 mutation to prevent its relapsing course. Despite spontaneous recovery in our patient, regular follow-up and continued monitoring are essential in tracking the patient's progress and ensuring the persistence of these positive outcomes over the long term as a small percentage of children may progress to ESRD.

Conflict of Interest

The authors declare that there is no conflict of interest regarding the publication of this paper.

Authors' Contribution

LP helped in the collection of clinical and laboratory data. SKP drafted and revised the manuscript.

References

- [1] Noris M, Remuzzi G. Hemolytic uremic syndrome. *J Am Soc Nephrol* 2005; 16: 1035.
- [2] Noris M, Caprioli J, Bresin E, et al. The relative role of genetic complement abnormalities in sporadic and familial aHUS and their impact on clinical phenotype. *Clin J Am Soc Nephrol* 2010; 5: 1844.
- [3] Tarr PI, Gordon CA, Chandler WL. Shiga-toxin-producing *Escherichia coli* and haemolytic uraemic syndrome. *Lancet* 2005; 365: 1073-86.
- [4] Kavanagh D, Goodship TH, Richards A. Atypical haemolytic uremic syndrome. *Semin Nephrol* 2013; 33: 508-30.
- [5] Geerdink LM, Westra D, van Wijk JA, et al. Atypical hemolytic uremic syndrome in children: complement mutations and clinical characteristics. *Pediatr Nephrol* 2012; 27: 1283.

- [6] Liszewski MK, Atkinson JP. Complement regulator CD46 genetic variants and disease associations. *Hum Genomic* 2015; 9: 7.
- [7] Richards A, Kathryn Liszewski M, Kavanagh D et. al. Implications of the initial mutations in membrane cofactor protein (MCP; CD46) leading to atypical hemolytic uremic syndrome. *Mol Immunol* 2007; 44: 111–22.
- [8] Vilalta R, Al-Akash S, Davin J, et al. Eculizumab therapy for pediatric patients with atypical hemolytic uremic syndrome: efficacy and safety outcomes of a retrospective study [abstract 1155]. *Haematologica*. 2012; 97 (suppl 1): 479.
- [9] Greenbaum LA, Fila M, Ardissino G, et al. Eculizumab is a safe and effective treatment in pediatric patients with atypical hemolytic uremic syndrome. *Kidney Int* 2016; 89: 701–11.
- [10] Noris M, Remuzzi G. Atypical hemolytic-uremic syndrome. *N Engl J Med* 2009; 361: 1676.
- [11] Nayer A, Asif A. Atypical Hemolytic-Uremic Syndrome: A Clinical Review. *Am J Ther* 2016; 23 (1): e151-e158.
- [12] Yoshida Y, Kato H, Ikeda Y, Nangaku M. Pathogenesis of Atypical Hemolytic Uremic Syndrome. *J Atheroscler Thromb* 2019; 26 (2): 99-110.
- [13] Klämbt V, Gimpel C, Bald M, et al. Different approaches to long-term treatment of aHUS due to MCP mutations: a multicenter analysis. *Pediatr Nephrol* 2021; 36: 463.
- [14] Caprioli J, Noris M, Brioschi S, et al. Genetics of HUS: the impact of MCP, CFH, and IF mutations on clinical presentation, response to treatment, and outcome. *Blood* 2006; 108: 1267.
- [15] Sellier-Leclerc AL, Fremeaux-Bacchi V, Dragon-Durey MA, et al. Differential impact of complement mutations on clinical characteristics in atypical hemolytic uremic syndrome. *J Am Soc Nephrol* 2007; 18: 2392.
- [16] Gurevich E, Landau D. Pharmacological Management of Atypical Hemolytic Uremic Syndrome in Pediatric Patients: Current and Future [published online ahead of print, 2023 Jan 13]. *Paediatr Drugs* 2023; 1-10.
- [17] Loirat C, Frémeaux-Bacchi V. Atypical hemolytic uremic syndrome. *Orphanet journal of rare diseases* 2011; 6: 1-30.