

# A Rare Case of Non Classic Congenital Adrenal Hyperplasia with Systemic Lupus Erythematosus in a 14-year-old Girl

**Maria Angela Yustina Fernandez, I Made Arimbawa\*, I Made Darma Yuda\*, Ketut Dewi Kumara Wati\***

Department of Pediatrics, Faculty of Medicine, Udayana University, Denpasar, Indonesia

## Email address:

angel.fernandez11@yahoo.com (Maria Angela Yustina Fernandez), maderimawa@gmail.com (I Made Arimbawa),

darmayuda.made@gmail.com (I Made Darma Yuda), ketutdewi@yahoo.com (Ketut Dewi Kumara Wati)

\*Corresponding author

## To cite this article:

Maria Angela Yustina Fernandez, I Made Arimbawa, I Made Darma Yuda, Ketut Dewi Kumara Wati. A Rare Case of Non Classic Congenital Adrenal Hyperplasia with Systemic Lupus Erythematosus in a 14-year-old Girl. *American Journal of Pediatrics*.

Vol. 8, No. 4, 2022, pp. 201-206. doi: 10.11648/j.ajp.20220804.12

**Received:** August 23, 2022; **Accepted:** September 7, 2022; **Published:** October 14, 2022

---

**Abstract:** *Introduction:* Congenital Adrenal Hyperplasia (CAH) is classified into salt-wasting (SW), simple virilising (SV) CAH and Non Classic Congenital Adrenal Hyperplasia (NC-CAH). This disease can present with autoimmunity disorders but very little has been reported. We reported a girl with NC-CAH who presented with a life-threatening condition. She was recovered well after proper diagnosis and therapy. *Case:* A 14 year old girl came with chest pain and shortness of breath revealed a severe pericardial effusion and impending cardiac tamponade. Further evaluation showed acute malar rash, non scarring alopecia, proteinuria > 0.5 gram/24 hours and hemolytic anemia. Laboratory confirmation showed ANA (IF) pattern: speckled with titer 1:100, ANA Profile revealed Sm (Sm) antigen (+) and Jo-1 (Jo) antigen (+++), C3 84.2 mg/dL and anti-dsDNA < 10 IU /mL. She was fulfilled Systemic Lupus International Collaborating Clinics (SLICC) 2015 and European League Against Rheumatism (EULAR) 2019 criteria for Systemic Lupus Erythematosus (SLE). At the same time, we also noticed about the excessive terminal hair (hirsutism) on the sideburns, upper lips, chin, chest, midline stomach, pubic, hands and legs on her. Further investigation was done to rule out the caused of hirsutism and masculinization. Investigation of testosterone was high 1.202 ng/dL, 17-OH progesterone 63.87 ng/mL, LH < 0.1 mIU/mL, FSH < 0.1 mIU/mL and estradiol 76 pg/mL. These revealed she suffered from NC-CAH. After treatment with pericardiostomy, high dose of methylprednisolone, cyclophosphamide and hydrocortisone, she recovered completely. *Conclusion:* Hirsutism is one of the symptoms of late-onset NC-CAH. Children with NC-CAH are at risk of developing autoimmune disorders because the genetic defect that occurs is in a highly active in the immune system.

**Keywords:** Hirsutism, Non Classic Congenital Adrenal Hyperplasia (NC-CAH), Systemic Lupus Erythematosus (SLE)

---

## 1. Introduction

CAH is an autosomal recessive disorder caused by mutations in genes encoding enzymes involved in cortisol biosynthesis pathways. The enzyme deficiency lead to multiple hormonal imbalances and manifests with a range of clinical and biochemical phenotypes, with or without alterations in glucocorticoid, mineralocorticoid, and sex steroid production [1]. The mutations cause considerable (non-classic form) to almost complete (classic form)

inhibition of enzymatic activity. More than 95% cases of CAH are due to mutations in *CYP21A2* gene and subsequent 21 $\alpha$ -hydroxylase deficiency, characterized by impaired cortisol synthesis and adrenal androgen excess [2]. CAH is clinically classified into the classic form and the NC-CAH. The classic form is subdivided into SW and SV CAH. Lethal salt crisis in the neonatal period will potentially develop in untreated infants with SW CAH and both SW and SV CAH cause prenatal virilisation of external genitalia in 46, XX foetus. Prenatal virilisation

does not occur in NC-CAH; instead, the first symptoms usually present after 60 months of age. NCAH typically has 20–70% residual 21-hydroxylase enzyme activity and therefore results in a less severe phenotype than classic CAH. The enzyme deficiency cause mild cortisol deficiency that lead to a reduced feedback inhibition on the pituitary with increased ACTH production and excess androgen synthesis as the result [3]. The classic forms incidence is reported between 1:5000 to 1:15,000 and varies among ethnic/racial backgrounds. NC-CAH is more common with an incidence of 1:1000 and increased prevalence among Hispanics, Yugoslavs, and Ashkenazi Jews [4].

SLE is an autoimmune rheumatic disease characterized by widespread inflammation and presenting autoantibodies affecting multiorgan system. The disease is associated with deposition of autoantibodies and immune complexes, resulting in tissue damage. Three mechanisms of SLE include a deficiency of complement, overproduction of interferon- $\alpha$  (IFN- $\alpha$ ) and damage mechanisms apoptosis [5, 6]. The annual incidence of SLE in the United States is 5.1 per 100,000 inhabitants, while the prevalence of SLE reported 52 cases per 100,000 inhabitants, with predominantly affects females, with ratio 9-14:1 [5]. SLE occurrence in children and adolescents is reported lower than the adults but tend to have more severe diseases than adult [6].

CAH is interesting from an immunological perspective in several ways. 21-hydroxylase deficiency (21OHD) is the most common variant of CA. It accounts for 95% to 99% of all CAH cases and is caused by recessive mutations in the CYP21A2 gene. The CYP21A2 gene is located in the HLA class III region in the major histocompatibility locus on chromosome 6 (p21.3). The genes responsible for the fourth component of complement and is highly active in the immune system. Autoimmune disorders have been associated with a low C4 copy number. Thus, it could be suspected that autoimmune disorders may present in 21OHD, but very little has been reported, and if mentioned, little or no details of the autoimmune disorders have been provided [7]. This case reported a girl with NC-CAH and SLE who presented with a life-threatening condition.

## 2. Case

A 14-year-old female was admitted to emergency room (ER) with chest pain. She felt chest pain all over the chest since 17 days prior to hospital admission that increased in 2 days. Chest pain felt like pressure. Pain worsened when she took a deep breath and improved with leaning forward. Fever, joint pain, cough and runny nose previously was denied. A week ago the parents noticed redness on both of her cheeks. The redness appeared suddenly and was not itchy nor related of cosmetics or facial creams. The stomach looked enlarged and felt bloated since 7 days ago. Hair loss was noticed since 1 week ago. History of canker sores or wound around mouth was denied.



**Figure 1.** The appearance of hirsutism in patient.

On initial evaluation, the blood pressure was 120/80 mmHg (P90-95), heart rate 108 beats/minute, regular and adequate. She was alert with respiratory rate 28 breaths/minute and normal body temperature. Further evaluation revealed non-scarring alopecia and malar rash on both cheeks. Her anthropometric status with body weight 51 kg, height 140 cm and body mass index 26.02. Laboratory investigation with White Blood Cell (WBC)  $7.67 \times 10^3/\mu\text{L}$ , Haemoglobine (Hb) 11.23 g/dL, platelets 317.10 with blood smear result mild normochromic normocytic anemia. Kidney function showed blood urea nitrogen (BUN) 36.40 mg/dL, creatinine serum 1.17 mg/dL with glomerular filtration rate 70.5 ml/min/1.73m<sup>2</sup>. On urinalysis we found leukocyte (3+) 300 mg/dL, proteinuria (3+) 300mg/dL (1-2 gram/day), erythrocyturia (blood (3+)). Liver function test showed SGOT 79.8 U/L, SGPT 183.40 U/L, total bilirubin 0.52 mg/dL, direct bilirubin 0.25 mg/dL, indirect bilirubin 0.27 mg/dL and albumin 3.10 g/dL. Electrolytes were normal, blood gas analysis with result pH 7.43, pCO<sub>2</sub> 22.7 mmHg, pO<sub>2</sub> 99.70 mmHg, HCO<sub>3</sub><sup>-</sup> 14.90 mmol/L. Echocardiography revealed severe loculated pericardial effusion at lateral and inferior left ventricel and impending cardiac tamponade. Further investigation revealed ANA (IF) pattern: speckled, titer 1:100, ANA Profile were Sm (Sm) antigen (+) and Jo-1 (Jo) antigen (+++), C3 84.2 mg/dL, and anti-dsDNA <10 IU /mL. She fulfilled 6 criteria of SLE based on SLICC 2015 criteria (malar rash (2), non-scarring frank alopecia (1), pericarditis (1), proteinuria  $\geq$  +3 (1) and hemolytic anemia (1).

In the same time she also looked have excessive terminal hair on the sideburns, upper lips, chin, chest, midline stomach, pubic, hands and legs. It said had been visible since childhood. Her father's sisters also have fine hairs all over the body, so the family consider this was normal. Some laboratories investigation were done to ruled out the diagnosis. Her testosterone hormone was high 1.202 ng/dL, 17-OH progesterone 63.87 ng/mL, LH <0.1 mIU/mL, FSH <0.1 mIU/mL and estradiol 76 pg/mL. Abdominal ultrasound revealed congestive hepatopathy, ascites, bilateral minimal pleural effusion, pericardial effusion, uterus and adnexa were normal. Bone age investigation showed it was accordance with the description of girls 16-17 years old (early puberty).

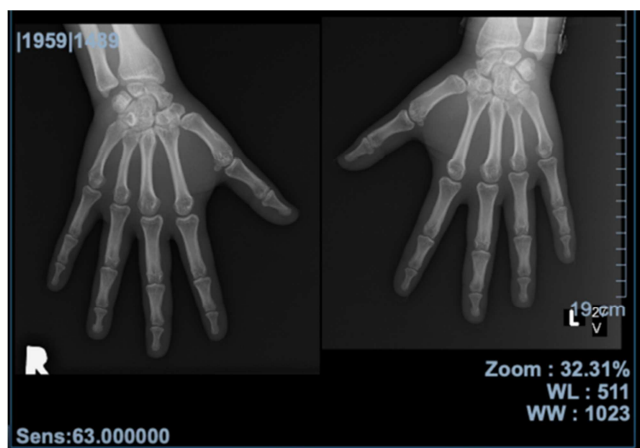


Figure 2. Bone age.

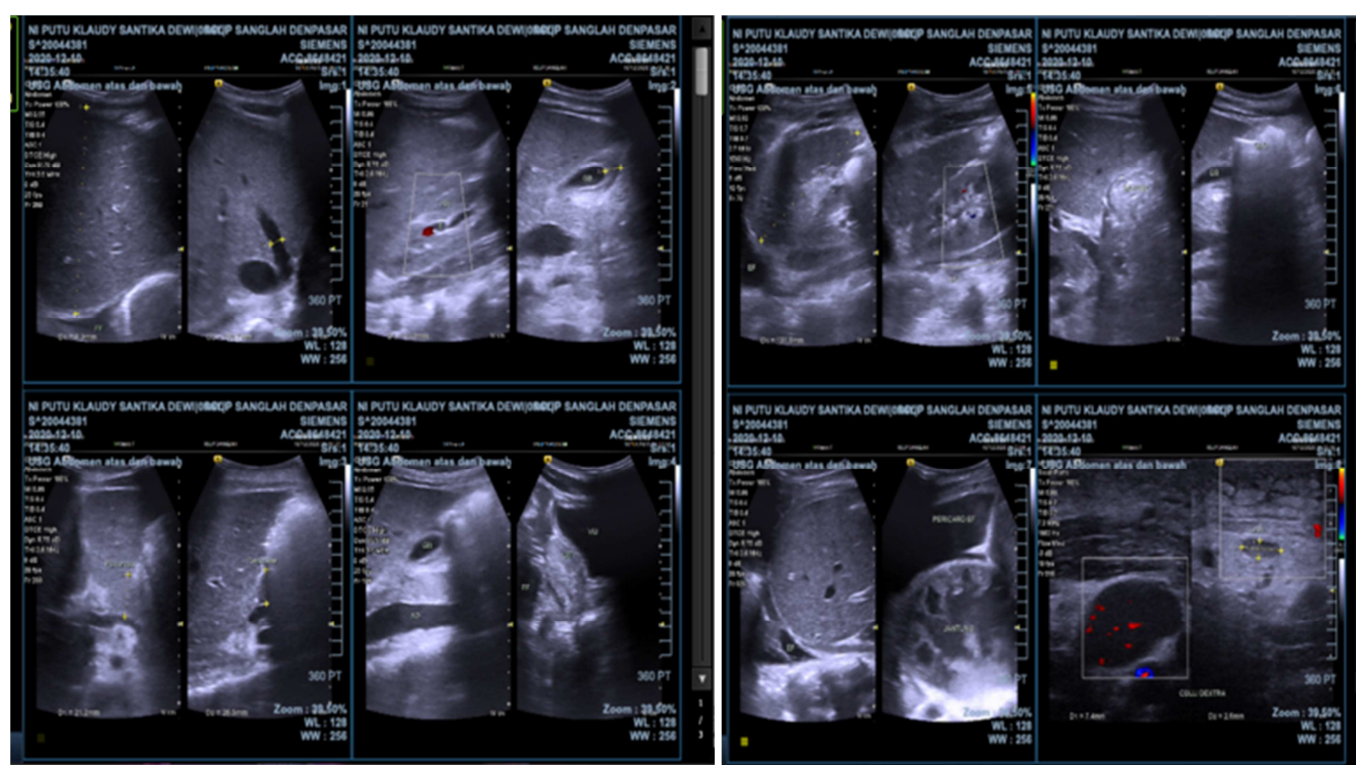


Figure 3. Ultrasonography abdomen.

### 3. Discussion

Mutation of the CYP21A1 gene is the most cause of CAH. This results in an enzyme deficiency in the adrenal cortex leading to 21-OHD, in over 90% of the cases. This disease is hallmark by an excessive androgen production, resulting from the impaired or no conversion of 17-hydroxyprogesterone (17OHP) to 11-deoxycortisol and of progesterone to deoxycorticosterone [8].

Virilization is the hallmark of 21-OHD. The severe classic form is characterized by marked overproduction of adrenal androgens. This ranges from enlargements of clitoris to complete fusion of the folds with the appearance of a penile

urethra. Increased pigmentation at the skin creases and genitalia caused by increased ACTH may alert clinician to the presence of adrenal insufficiency. In classic 21-OHD, inadequate hydroxylation of progesterone to 11-deoxycorticosterone results in aldosterone deficiency, and a salt-wasting crisis may occur. Poor weight gain is the early symptom but most infants with severe CAH develop vomiting, severe dehydration and shock by the second or third week of life. This may lead to death of infant if not treated properly [9]. In comparison to the symptoms of the classical form, most cases of NC-CAH are not easily detectable. Most women with NCCAH seek medical assistance when they experience symptoms of androgen excess [10].

Finally, we diagnosed the patient as definitive SLE, severe loculated pericardial effusion, pleural effusion, hypertension stage II, nephritis lupus, AKI stage risk, NC-CAH, asymptomatic of urinary tract infection, overweight. She was given high dose of methylprednisolone 30mg/kg for 3 days intravenous, cyclophosphamide 500mg intravenous, furosemide 40mg TID intravenous, hydrocortisone 20mg-0-10mg for 3 days and continuous with dose 10mg-0-10mg oral, cefixim 100mg BID oral, kaptopril 25mg BID oral, amlodipin 5mg OD oral and also surgical procedures include pericardiotomy and thoracostomy inserted water sealed drainage (WSD). She was recovered well after these treatment. Upon discharge, hydrocortisone still gave 2 times a day with dose 10mg in the morning and 10mg in the evening. The next management of SLE was cyclophosphamide every 2 weeks for 3 months then continued every 3 months.

Late-onset, NC-CAH is usually diagnosed later on during childhood or adolescence or even in adulthood. The symptoms of androgen excess may start during childhood or later in life. The spectrum of symptoms at diagnosis is related to age. In children aged younger than 10 years, preterm adrenarche was most common (87%), while female adolescents may present with severe acne, hirsutism, androgen alopecia, clitoromegaly (11%), irregular menstruation (56%) or even primary amenorrhoea (9%). In adolescents and adults, typical presenting symptoms are acne, hirsutism, oligomenorrhea or infertility [3]. Hirsutism is defined medically as excessive terminal hair that appears in a male pattern (i.e., sexual hair) in women. About 5 percent of women of reproductive age in the general population are hirsute, as indicated by a score of 8 or more on the Ferriman–Gallwey scale, which quantitates the extent of hair growth in the most androgen sensitive sites [11].

SLE is an autoimmune disease. A complex interaction of impaired apoptotic clearance, upregulation of innate and adaptive immune system, complement activation, immune complexes, and tissue inflammation culminates in a self-sustained autoimmune process. Many environmental triggers have been implicated in lupus. Ultraviolet light (the most recognized), drugs/supplements (echinacea, trimethoprim/sulfamethoxazole), smoking, infections (Epstein-Barr virus in particular), silica, mercury and others. Psychological stress has also been linked to a 50% increase risk of developing lupus [12]. Many organ systems can be involved in patient with SLE, so the possible first clinical manifestation could not be predicted. The common manifestation of SLE include discoid rash, malar rash, alopecia, photosensitivity, oral or nasal ulcer, myalgia, polyarthralgia/polyarthritis, pericarditis/pleuritis, peritonitis, leucopenia, thrombocytopenia, hemolytic anemia, proteinuria, hematuria, azotemia, psychosis/seizures, cranial or peripheral neuropathies [13-15].

Diagnosis of SLE is based on clinical and laboratory data of the latest updated SLICC 2015 criteria. The SLICC criteria for SLE classification require fulfillment of at least 4 criteria with at least 1 clinical criteria and 1 immunologic criteria has 98.7% sensitivity and 85.3% specificity [13, 16]. The patient with total point 4 of 16, has definite diagnosis of SLE, 3 points highly suggestive SLE, 2 points probable SLE, and 1 point was possible SLE [17]. Other than SLICC criteria there is new classification criteria to diagnose SLE supported by EULAR and the American College of Rheumatology (ACR) 2019. A patient is classified to SLE if fulfilled minimal 10 scores from this criteria [18].

In this case, at diagnosis she fulfilled 6 points of 16 SLICC criteria 2015 (definitive SLE). Clinical manifestation of SLE at the time of initial diagnosis were malar rash (2), non scarring alopecia (1), proteinuria +3 (>0.5 gram/24 hours (1) and hemolytic anemia (1). Laboratories investigation revealed ANA (IF) pattern: speckled with titer 1:100, ANA Profile with Sm (Sm) antigen (+) and Jo-1 (Jo) antigen (+++), C3 84.2 mg/dL, anti-dsDNA <10 IU /mL). Based on EULAR classification,

the total score was 24 (non-scarring alopecia (2), acute cutaneous lupus (6), acute pericarditis (6), proteinuria >0.5gram/24 hours (4), anti-Smith antibody (6)). In the same time we noticed about the excessive terminal hair (hirsutism). It said had been visible since childhood. She had her first menstruation at 11 years old. Menstruation was regular and no complain. There was no history of consume any drugs. The scoring of hirsutism based on The ferriman-Gallwey Scoring System for Hirsutism was 19. Further evaluation revealed she was short stature. Her height was below -2 SD. Her potential genetic height was 147.5 until 164.5 cm. Her arm span was 143 cm, upper body segment 62 cm and ratio between upper and lower segment 0.7. Her height was below her potential genetic height. Her puberty state was tanner stage 4. The hirsutism was suspected caused by hyperandrogenism. Investigation of testosterone hormone was high 1.202 ng/dL, 17-OHP 63.87 ng/mL, LH <0.1 mIU/mL, FSH <0.1 mIU/mL and estradiol 76 pg/mL. Abdominal ultrasound showed uterus and adnexa were normal. Bone age investigation showed it was accordance with the description of girls 16-17 years old (early puberty).

Hirsutism typically results from abnormal high androgen levels as a result of increased production of androgens. Some causes of hirsutism are adrenal disorders (NC-CAH), androgenic drugs, ectopic hormone production and ovarian disorders like Polycystic Ovary Syndrome (PCOS). Overall, the most common cause is PCOS. In this case, some laboratories investigation was done to ruled out the cause of hirsutism [11]. According to the Rotterdam criteria, diagnosis of PCOS requires the presence of at least two of the following three findings: hyperandrogenism, ovulatory dysfunction and polycystic ovaries. In this case only have one criteria hyperandrogenism. Therefore diagnosis of PCOS can be ruled out.

CAH is marked by elevated level of 17OHP. It is the biochemical hallmark of 21-hydroxylase deficiency and the main substrate for the 21-hydroxylase enzyme. Classic CAH is now mainly diagnosed by screening and not by symptoms alone, especially in countries with neonatal screening. When the diagnosis of CAH is suspected later in childhood or in an adult, screening with an early morning 17OHP should be the first investigation. A value of less than 2.5nmol/L in children and less than 6.0nmol/L in adults has been suggested to exclude CAH [3]. In this case, we suspected CAH because we found hirsutism, short stature and masculinization. The result of increased 17-OHP is a gold standard to diagnose NC-CAH.

However, most patients have sought medical attention for their symptoms. The majority of individuals diagnosed with NCAH will receive some kind of treatment, at least for a certain period of time. In school children and adolescence, severe acne, hirsutism, androgen alopecia, clitoromegaly, history of growth acceleration and menstrual irregularities are indication for treatment. Growth velocity, weight, blood pressure, bone age and measurement of 17-OHP should be evaluated regularly [3].



Hydrocortisone has less negative effect on growth so it is recommended in treatment of children with CAH. The recommended hydrocortisone dose is 10–15 mg/m<sup>2</sup> body surface for classic CAH and is higher in adolescence. The doses required for patients with NC-CAH to ameliorating the androgen excess are often substantially lower [3]. In this case, the patient had given hydrocortisone 20mg-0-10mg for 3 days and continuous with dose 10mg-0-10mg oral. She was recovered well with this treatment. One month later on evaluation in polyclinic, there were no complaint and hirsutism is getting better.

Treatment goals in SLE are to control inflammation, achieve remission condition (without clinical manifestation), improve quality of life, no severe exacerbation, prevent serious organ damage and reduce mortality rate. The initial treatment in the first 4-6 weeks is indicated for severe condition, by using 30 mg/kg/dose intravenous methylprednisolone in 60 minutes for 3 days concomitantly or prednisone tablet 15-60 mg/day (0.5-2 mg/kg/day) in two doses then continue with prednisone or methylprednisolone in tapering dose, in combination with administration of Disease Modifying Anti Rheumatic Drugs (DMARDs), which include Cyclophosphamide pulse given in combination with methylprednisolone pulse dose; Mycophenolate mofetil (MMF) can be given after methylprednisolone pulse as sparing steroid while tapering; Azathioprine can be given after completion of cyclophosphamide or after six months of first MMF with daily dose 0.5-2.5 mg/kg/day orally for 6 months [15, 16]. In this case, patient was given methylprednisolone pulse dose for 3 days, continued with cyclophosphamide and tapering off methylprednisolone. Cyclophosphamide 500 mg per time intravenously will be given every two weeks for three months, followed by cyclophosphamide maintenance every 3 months.

CAH is interesting from an immunological perspective in several ways. The most common variant of CAH, 21OHD accounts for 95% to 99% of all CAH cases and is caused by recessive mutations in the CYP21A2 gene which is located in the HLA class III region in the major histocompatibility locus on chromosome 6 (p21.3). The genes responsible for the fourth component of complement and is highly active in the immune system. Autoimmune disorders have been associated with a low C4 copy number. Women with CAH are exposed to higher androgens levels than controls, which could have a "masculinizing" effect, or a less activating effect on the immune system. An androgen effect may be related to a lower risk of developing an autoimmune disease, which would counteract any other effect by, for example, CAH resulting in increasing autoimmunity. In conclusion, a female with NC-CAH may also have an autoimmunity disorders. Many times, the symptoms of androgen excess are not realized and considered to be normal because of other family member have the similar symptoms. The diagnosis of these two conditions could only be known when there are disturbing or even life-threatening symptoms. Both condition may have good prognosis with prompt diagnosis and treatment.

## 4. Conclusion

Hirsutism is one of the symptoms of late-onset NC-CAH. Children with NC-CAH are at risk of developing autoimmune disorders because the genetic defect that occurs is in a highly active in the immune system.

## Conflict of Interest

All the authors do not have any possible conflict of interest.

## References

- [1] El-Maouche D, Arlt W, Merke DP. Congenital adrenal hyperplasia. *The Lancet*. 2017 May 30; 6736 (17): 1-9. doi: [https://doi.org/10.1016/s0140-6736\(17\)31431-9](https://doi.org/10.1016/s0140-6736(17)31431-9)
- [2] Suminska M, Bogusz-Gorna K, Wegner D, Fichna M. Non-classic disorder of adrenal steroidogenesis and clinical dilemmas in 21-hydroxylase deficiency combined with backdoor androgen pathway. Mini-review and case report. *Int. J. Mol. Sci.* 2020 June; 21 (4622): 1-16. doi: <https://doi.org/10.3390/ijms21134622>
- [3] Nordenström A, Falhammar H. Diagnosis and management of the patient with non-classic CAH due to 21-hydroxylase deficiency. Review. *European Journal of Endocrinology*. 2019; 180: R127-R145. doi: <https://doi.org/10.1530/eje-18-0712>
- [4] Witchel FS. congenital adrenal hyperplasia. *Journal of Pediatric and Adolescent Gynecology*. 2017.04.001. doi: <https://doi.org/10.1016/j.jpag.2017.04.001>
- [5] Gitelman MK, Lane C. Systemic lupus erythematosus. In: Petty RE, Laxer RM, Lindsley CB, Wedderburn LR, editors. *Pediatric Rheumatology*. 7<sup>th</sup> ed. Beijing: Elsevier; 2011. p. 285-316.
- [6] Rebecca ES, Stacy PA, Laura ES. Systemic lupus erythematosus. In: Kliegman RM, Bonita FS, Joseph WS, Nina FS, editors. *Nelson Textbook of Pediatrics*. 20<sup>nd</sup> ed. Philadelphia: Elsevier; 2016. p. 1176-80.
- [7] Falhammar H, Frisen L, Hirschberg AL, Nordenskjöld A, Almquist C, Nordenstrom A. Increased Risk of Autoimmune Disorders in 21-Hydroxylase Deficiency: A Swedish Population-Based national Cohort Study. 2019; 3 (5): 1039-1052. doi: <https://doi.org/10.1210/js.2019-00122>
- [8] Ferreira MJS. Quality of Life in Children Diagnosed with Non-Classic Congenital Adrenal Hyperplasia. *Clin Pediatr*. 2021 March; 6 (179): 1-6. doi: <https://doi.org/10.7759/cureus.18937>
- [9] Das JC, Khanam M, Islam R. Congenital Adrenal Hyperplasia: A Case Report. *JCMCTA*. 2013; 24 (2): 44-47
- [10] Livadas S, Bothou C. Management of the Female With Non-classical Congenital Adrenal Hyperplasia (NCCAH): A patient-Oriented Approach. *Front. Endocrinol*. 2019; 10 (366): 1- 11. doi: <https://doi.org/10.3389/fendo.2019.00366>
- [11] Rosenfield RL. Hirsutism. *N Engl J Med*. 2005; 353: 2578-2588. doi: <https://doi.org/10.1056/nejmc033496>
- [12] Fava A, Petri M. Systemic lupus erythematosus: diagnosis and clinical management. *J Autoimmun*. 2019; 96: 1-13. doi: <https://doi.org/10.1016/j.jaut.2018.11.001>

- [13] Bertsias G, Cervera R, Boumpas DT. Systemic lupus erythematosus: pathogenesis and clinical features. In: Bertsias G, Cervera R, Boumpas DT, editors. *Eular Textbook on Rheumatic Diseases*. 1<sup>st</sup> ed. London: Elsevier; 2010. p. 476-505.
- [14] Chiewchengchol D, Murphy R, Edwards SW, Beresford MW. Mucocutaneous manifestations in juvenile-onset systemic lupus erythematosus: a review of literature. *Pediatr Rheumatol* 2015; 13: 1-9. doi: <https://doi.org/10.1186/1546-0096-13-1>.
- [15] Ambrose N, Morgan T, Galloway J, Lonnoau Y, Beresford M, Isenberg D. Differences in disease phenotype and severity in SLE across age groups. *Lupus Sci Med*. 2016; 25: 1542-50. doi: <https://doi.org/10.1177/0961203316644333>
- [16] Abari IS. 2015 ACR/SLICC revised criteria for diagnosis of systemic lupus erythematosus. *Autoimmune Dis Ther Approaches*. 2015; 2: 1. doi: <http://dx.doi.org/10.14437/ADTAOA-2-114>
- [17] Kasjmir YI, Handono K, Wijaya LK, Hamijoyo L, Albar Z, Kalim H, et al. *Diagnosis dan Pengelolaan Lupus Eritematosus Sistemik*. 1<sup>st</sup> ed. Jakarta: Perhimpunan Reumatologi Indonesia; 2011. p. 8-9.
- [18] Aringer M, Costenbader K, Daikh D, Brinks R, Mosca M, Ramsey-Goldman R, et al. 2019 European League Against Rheumatism/American College of Rheumatology Classification Criteria for Systemic Lupus Erythematosus. *Arthritis & Rheumatology*. 2019; 0 (0): 1-13. doi: <https://doi.org/10.1136/annrheumdis-2018-214819>.