



Method of Correction of Meconium Peritonite and Its Complications During Pregnancy and After Birth (Clinical Case)

Ovsyanikov Philipp Andreevich^{1, *}, Ryabokon Nikita Romanovich¹, Bairov Vladimir Gireyevich², Sukhotskaya Anna Andreevna³, Zazerskaya Irina Evgenievna¹, Korolev Mikhail Vladimirovich¹

¹Department of Obstetrics and Gynecology, Almazov National Medical Research Centre, Ministry of Health, St. Petersburg, Russia

²Research Laboratory of Surgery for Congenital and Hereditary Pathology, Department of Surgical Diseases, Almazov National Medical Research Centre, Ministry of Health, St. Petersburg, Russia

³Department of Pediatric Surgery of Malformations and Acquired Pathology for Newborns and Infants, Almazov National Medical Research Centre, Ministry of Health, St. Petersburg, Russia

Email address:

siversl@yandex.ru (O. P. Andreevich)

*Corresponding author

To cite this article:

Ovsyanikov Philipp Andreevich, Ryabokon Nikita Romanovich, Bairov Vladimir Gireyevich, Sukhotskaya Anna Andreevna, Zazerskaya Irina Evgenievna, Korolev Mikhail Vladimirovich. Method of Correction of Meconium Peritonite and Its Complications During Pregnancy and After Birth (Clinical Case). *American Journal of Pediatrics*. Vol. 7, No. 4, 2021, pp. 211-218. doi: 10.11648/j.ajp.20210704.16

Received: September 11, 2021; **Accepted:** September 29, 2021; **Published:** November 27, 2021

Abstract: This article describes a clinical case of management of a pregnant woman with meconium peritonitis of the fetus and further observation and treatment of the child. Meconium peritonitis, being aseptic intrauterine peritonitis, is a serious disease that requires an integrated approach. The tactics in relation to the fetus, intrauterine risks and prognosis of survival in this pathology, as well as the possibility of choosing a method for correcting meconium peritonitis and its complications during pregnancy and after childbirth are discussed. With meconium peritonitis, timely prenatal diagnosis is extremely important, which significantly improves the prognosis and allows prenatally to take measures aimed at stabilizing the condition of the fetus and the pregnant woman. On the example of this clinical case, an assessment was made of the possibility of reducing the risks of life-threatening complications, depending on the clinical course of peritonitis. Due to the appearance of ultrasound criteria of severity (meconium ascites, compression of the chest cavity of the fetus, dropsy and polyhydramnios), it became possible to predict the course of development of meconium peritonitis. The stages of pregnancy, childbirth and the neonatal period are described in detail, as well as the therapeutic and surgical correction of this severe pathology with further early rehabilitation.

Keywords: Meconium Peritonitis, Pregnancy, Amniolaparocentesis

1. Introduction

Meconium peritonitis (MP) is aseptic prenatal peritonitis resulting from bowel perforation in the II or III trimester of pregnancy. MP, being a rare and very serious disease of the neonatal period, was first described by Morgagni in 1761 and isolated as an independent nosological unit only in 1989. With perforation of the intestinal wall as a result of an inflammatory reaction in the abdominal cavity, aseptic peritonitis occurs, ascites is formed, adhesive process, cystic

formations. The frequency of occurrence of MP in the USA (1:35000 live births), in Germany (1:10000 - 1:15000, 1990). The incidence of meconium peritonitis in St. Petersburg is 1:14,000 live births. [1, 2].

MP can be diagnosed by detecting a hyperechoic multi-chamber formation, presenting to the anterior abdominal wall, is combined with polyhydramnios in 95-98% of cases. Prenatal diagnosis of MP is performed using ultrasound examination (ultrasound), by detecting the following ultrasound signs [1-5]:

- a. fetal ascites - in 100% of cases;

- b. the presence of calcifications in the abdominal cavity of the fetus - in 87% of cases;
- c. dilated fetal intestinal loops - in 99% of cases;
- d. the presence of pseudocysts and / or polyhydramnios - in 95% of cases.

With the improvement of the methods of diagnosis and treatment of MP, the survival rate increased from 30% to more than 90% [4, 5], which is due to the timely diagnosis in prenatal period. Mortality in cases where MP was diagnosed prenatally is about 7.1% [3, 6, 7].

A severe course of MP is also possible during prenatal development. Thus, a gradual increase in ascites or an increase in the size of a giant cyst in utero can lead to compression of the chest organs and cause hypoplasia of the lungs, also contribute to fetal anemization, which in turn can lead to severe distress in the fetus and its death at 32-35 weeks of pregnancy [14]. A number of foreign authors

suggest carrying out intrauterine drainage of the abdominal cavity and blood transfusion, since anemia and hypoproteinemia play an important role in the development of pathophysiological changes. However, the effectiveness and benefits of such treatment are still quite debatable. [By Tatsuo Kuroda et al., 2004; Ming-Kwang Shyu et al., 2003; T. Okawa et al., 2008]. A team of local authors (Voronin D. V, Mikhailov A. V, et al.) in 2013 proposed a tactic for managing pregnancy and childbirth in cases of suspected MP in the fetus from intrauterine diagnosis to the moment of delivery [8] (Figure 1).

Most foreign authors indicate prenatal diagnosis of MP as an important component that determines the strategy and tactics of pregnancy and childbirth management in women expecting a child with MP. Early detection and correct tactics can improve the prognosis for the patient [9].

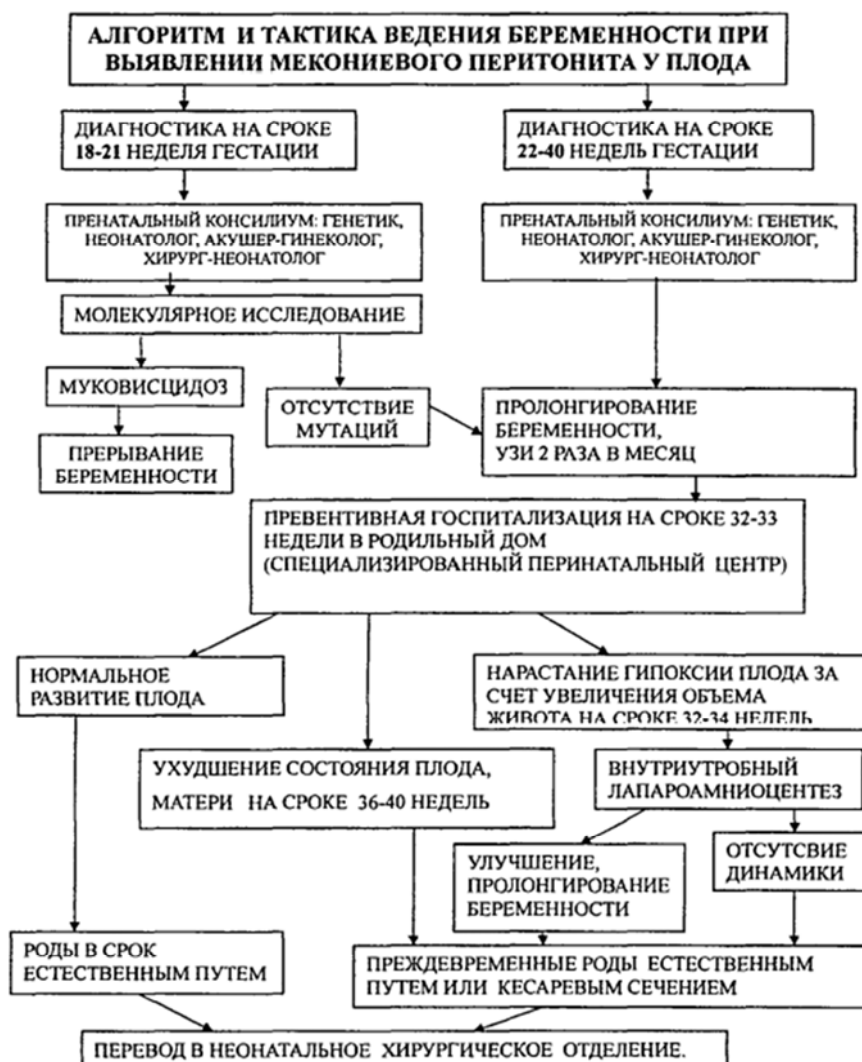


Figure 1. Scheme of pregnancy and childbirth management in the detection of meconium peritonitis.

Postnatally, there are three types of meconium peritonitis [Lorimer W. S. and Ellis D. G.]:

1. *Fibroadhesive form of peritonitis*, the most common one. Children are born in a stable condition and do not

have clinical manifestations of intestinal obstruction. On a plain radiograph of the abdominal cavity, calcifications are determined in almost 85% of them. These do not require any surgical intervention, however,

observation is necessary during the first year of life in connection with the possible development of intestinal obstruction at a later date.

2. *Pseudocystosis form of peritonitis* occurs with limited fibroplastic properties of the fetal peritoneum, meconium for a long time enters the free abdominal cavity. In this case, pseudocysts are formed, which consist of intestinal loops involved in the inflammatory process, and a fibrous capsule surrounding the intestine and tightly connected with the parietal peritoneum and parenchymal organs of the abdominal cavity. As a rule, pseudocysts occupy more than half of the volume of the abdominal cavity, more often localized in its right half.
3. *Generalized peritonitis* occurs with intestinal perforation at a later date or immediately before childbirth, meconium fills all parts of the abdominal cavity, and the process is not delimited. The clinical picture of pseudocystic and generalized peritonitis is characterized by symptoms of low intestinal obstruction. Abdominal distention rapidly increases, meconium does not leave, respiratory disorders join, generalization of the inflammatory process. [2, 6]

For the first time, a surgical method for the correction of meconial peritonitis was proposed in 1966 by Lorimer W. S. and Ellis D. G. developed options for surgical tactics for the treatment of MP. With the *fibroadhesive form* of MP, the excision of adhesions and resection of the damaged section of the intestine with the imposition of an anastomosis were proposed. In case of *pseudocystosis form* peritonitis, it was recommended to excise adhesions, to remove at least partially the walls of the pseudocyst and to resect the damaged section of the intestine, followed by the imposition of an intestinal stoma. [6] With the *generalized form*, it was proposed to excision the damaged segment of the intestine and impose an enterostomy.

The extremely serious condition of a newborn with MP that occurs immediately after birth makes it impossible to perform radical surgery. In these cases, laparocentesis is performed to relieve high intra-abdominal pressure. Drainage of the abdominal cavity in newborns with peritonitis in order to stabilize an extremely serious condition, which was proposed by S. Ein et al. in 1977 as the first stage of surgical treatment. [7]

Below we present the clinical observation and management of pregnancy with diagnosed meconium peritonitis in the fetus, when intrauterine laparoamniocentesis, performed in connection with a pronounced increase in fetal abdominal volume, high standing of the diaphragm domes and the threat of lung hypoplasia. This manipulation made it possible to prepare the child for surgery after birth, excluding the stage of preliminary drainage of the abdominal cavity in order to stabilize the condition of the newborn.

2. Clinical Case

Patient G., 17 years old, primigravida, primipara was

observed in the Federal Specialized Perinatal Medical Center of V. A. Almazov. In past medical history: chronic tonsillitis; abnormality in the development of the urinary system: left-sided hydronephrosis, left pyeloureteroplasty in 2004; vein disease - varicose veins; swelling of pregnant women; moderate anemia.

Gynecological history: menses from 11 years old were established immediately, for 5 - 7 days, after 28-30 days, moderate, painless, last menses 13.04.2019, EDD 18.01.2020. The patient was registered in the antenatal clinic from 7/8 weeks of gestation. During pregnancy, at a period of 5 weeks, she had an acute respiratory viral infection with an increase in body temperature to 37.5°C. At a period of 28 weeks, due to the threat of termination of pregnancy, she underwent a course of inpatient treatment.

The first screening, performed at 12/13 weeks, did not reveal any abnormalities in the development of the fetus. Repeated ultrasound performed at 20 5/7 weeks of gestation showed signs of isolated hypoplasia of the nasal bones in the fetus, and therefore a control ultrasound was recommended at 24-26 weeks of gestation. According to the results of an ultrasound study performed within the recommended time frame of 25 4/7 weeks of gestation, ultrasound signs of low intestinal obstruction in the fetus, dilated bowel loops, calcifications, ascites and polyhydramnios were established. Given these signs, meconial peritonitis was diagnosed. It was recommended prolongation of pregnancy, control ultrasound at 30 weeks of gestation, examination for latent infections.

An ultrasound examination was performed at 30 weeks of gestation. In the abdominal cavity of the fetus, multiple swollen intestinal loops (up to 6 cm) with anechoic contents and hyperechoic inclusions (calcifications) are determined. In the lower parts of the abdominal cavity, multiple pseudocysts with anechoic contents are located. Diagnosed with pregnancy 30-31 weeks; polyhydramnios, mixed breech presentation of the fetus; congenital malformation of the fetus - meconium peritonitis. Given the high risk of early delivery at 32 5/7 weeks of gestation, ARDS was prevented in the fetus with dexamethasone according to the scheme (total dose 24 mg). A control ultrasound scan was recommended in a week.

Control ultrasound at 33 5/7 weeks of gestation revealed an increase in the volume of the abdominal cavity with a high position of the domes of the diaphragm.

On 02.12.2019, she was urgently hospitalized in the Pathologic Pregnancy Department of the Almazov National Medical Research Centre Ministry of Health due to the negative dynamics of ultrasound indicators (an increase in amniotic fluid and abdominal circumference), a prenatal consultation was held, where a decision was made on intrauterine intervention. 1 hour before the operation and 2 hours after the patient received a rectal suppository with indomethacin. Antibacterial prophylaxis with intravenous sultasin was performed 30 minutes before the operation. The patient underwent amniolaparocentesis procedure, amnioreduction under local anesthesia with lidocaine solution.

Surgical record— under ultrasound navigation with an needle (18G caliber) in the placenta-free area, at the first stage, 3000 ml of light-yellow amniotic fluid was removed. The fetus is anesthetized with an intramuscular injection of fentanyl. At the second stage, amniolaparocentesis was performed through the anterior abdominal wall of the fetus. 600 ml of dark yellow liquid was evacuated. The material was sent for microbiological and bacterial research, according to the results of which a bacterial or viral agent was not detected. Free fluid in the abdominal cavity of the fetus is not detected. The standing level of the fetal diaphragm has shifted towards the abdominal cavity. The needle was removed from the abdominal cavity of the fetus.

The fetal heartbeat is 144 beats per minute, rhythmic. The infusion of tocolytics was continued for 6 hours. The patient was transferred to the Pregnancy Pathology Department, where she continued to monitor the condition of the fetus 2 times a week.

After 2 weeks (19.12.2019), according to ultrasound data, at 35 5/7 weeks of gestation, increasing polyhydramnios with a pronounced increase in abdominal circumference in the fetus was revealed in dynamics (Table 1, Figures 2, 3). At the prenatal consultation indications for repeated laparoamniocentesis in order to reduce intra-abdominal pressure of the fetus.

Table 1. Protocol of ultrasound examination at 35 5/7 weeks.

In the uterine cavity, one fetus is determined in breech presentation.

Fetal heart rate: 144 bpm

The biparietal head size is 91 mm.

Head circumference 331 mm.

The frontooccipital size is 114 mm.

Abdominal circumference 401 mm.

Femur length 65 mm.

The length of the humerus is 56 mm.

The estimated weight of the fruit is 3100 gram

The placenta is located along the anterior wall.

Polyhydramnios.

Amniotic index 260 mm.

The cervical canal, 30 mm., The internal pharynx is not dilated.

The myometrium is homogeneous, the echo structure is not changed.

Ultrasound signs of intrauterine peritonitis in the fetus (dilated fetal intestinal loops, ascites, calcifications).

The maximum vertical pocket of fluid in the abdominal cavity of the fetus is 65 mm.

There are no violations of the fetal-placental blood flow.

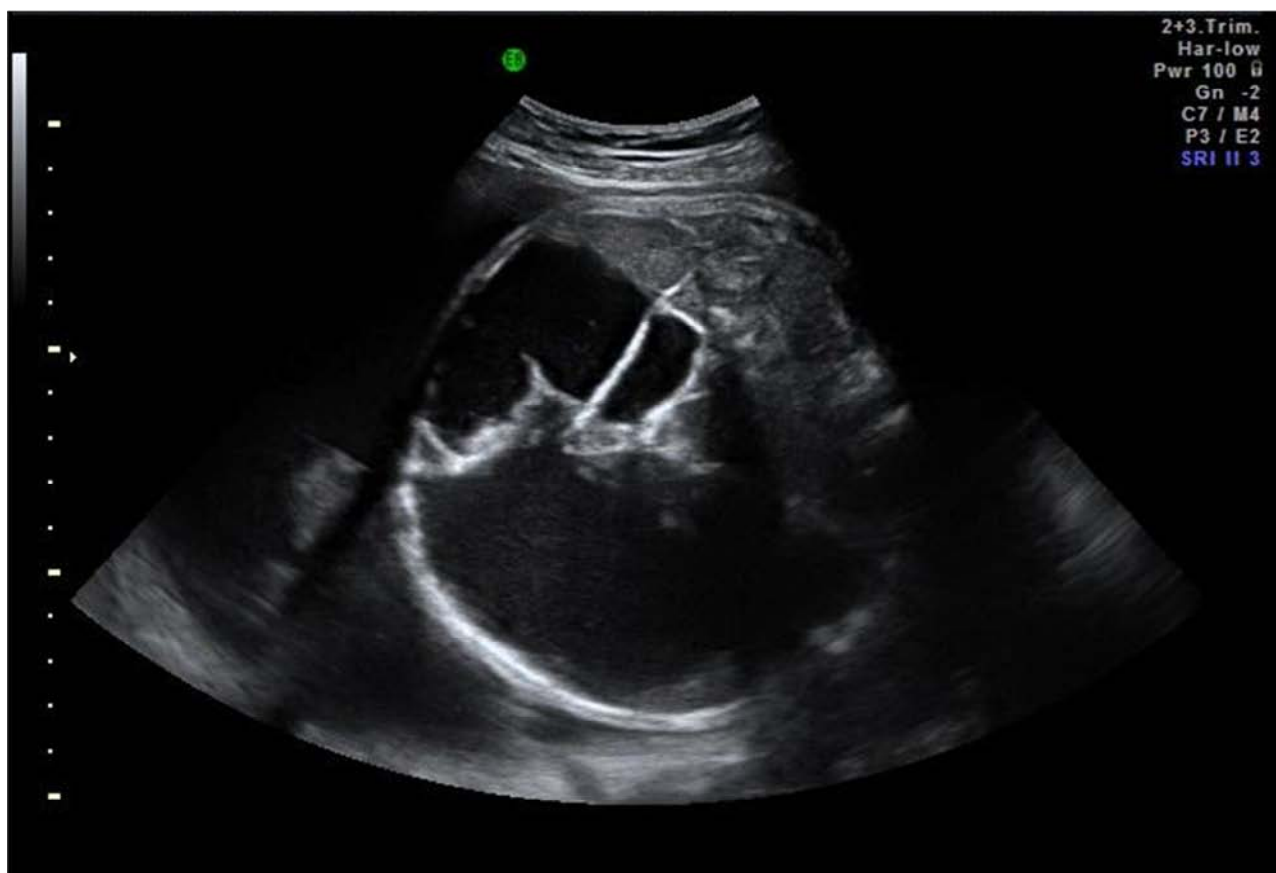

Figure 2. III screening ultrasound at 35 5/7 weeks of gestation.

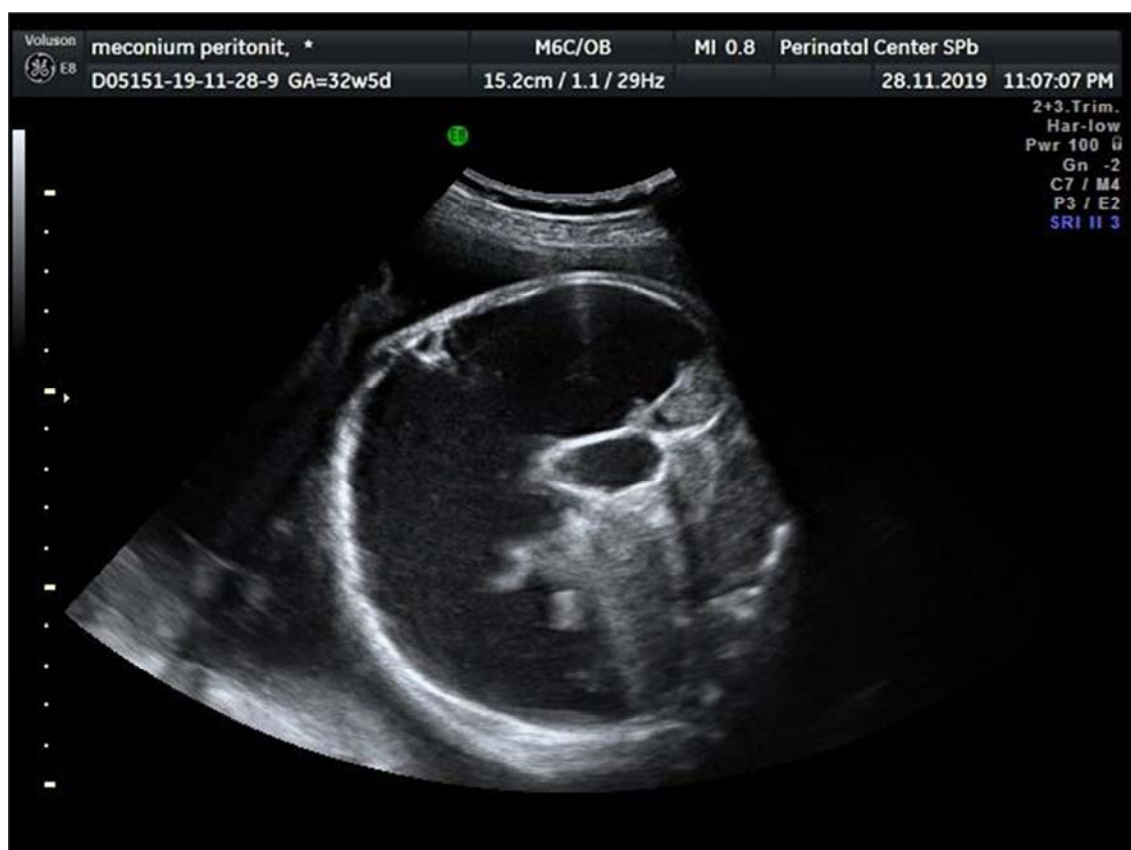

Figure 3. III screening ultrasound at 35 5/7 weeks of gestation.

Amniolaparocentesis and amnioreduction were performed again. Against the background of intravenous administration of tocolytics, under local anesthesia with 2% lidocaine solution, puncture was performed of the anterior abdominal wall of the mother. After reaching the amniotic cavity, the mandrel was removed and puncture was performed using a G22 needle and the fetal peritoneal fluid was taken in a brown-green color, with a small amount of suspension, in a volume of 500 ml. The material was sent to the laboratory for bacteriological examination. Amnioreduction of amniotic fluid was performed in a volume of 300 ml. The fetal heartbeat is recorded, rhythmic, 150 beats per minute. The study of the peritoneal fluid did not reveal any agents of bacterial or/and viral etiology.

On December 20, at a gestation period of 35 6/7 weeks, due to the onset of premature labor, refractory to tocolysis with ginipral, in a primiparous woman with a foot presentation of the fetus, indications were displayed and a caesarean section was performed in the lower segment of the uterus on an emergency basis. A live premature boy, weighing 2730 grams, length 43, head circumference 34 cm, chest circumference 29 cm, was easily retrieved by the legs. The Apgar score was 6/7 points. The placenta was located along the anterior wall of the uterus. The afterbirth was removed by hand and had the appearance of “boiled meat” with an ichorous odor. Conclusion of the histological examination of the placenta: the morphofunctional state of the placenta is subcompensated chronic placental insufficiency with acute circulatory disorders. Infectious

changes: focal villusitis, productive chorodeciduitis, productive basal deciduitis. The prognosis: the risk for the mother for endometritis - yes. The risk for the child is medium in terms of hypoxia; on adaptation - average; for intrauterine infection - high;

The child's condition at birth is severe due to respiratory failure, meconium peritonitis (Figure 4). At birth, heart rate 80 per minute, cough, short cry, irregular breathing, diffuse cyanosis, hypotension, hyporeflexia. The child was intubated with ETT No. 3 to a depth of 8.5 cm, AssV was started with parameters FiO_2 0.21->0.3, PIP +20, PEEP +6, Rate 40 per minute. By the end of 1 min, heart rate >100 / min, irregular breathing, began to turn pink. A gastric tube is installed, the discharge is stained with blood. AssV continued. Auscultatory breathing is carried out on the left in all departments, on the right - in the upper, in the lower ones, weakened, the chest excursion is insufficient. Abdominal circumference 40 cm with a chest circumference of 29 cm, not tense, pronounced venous network on the abdomen. By the end of the 5th minute, heart rate 150 per min, turned pink. At the 20th minute of his life on AssV in a transport incubator, he was transferred to anesthesiology-critical care, accompanied by a resuscitator. In the intensive care unit, the condition was stabilized, an ultrasound scan of the abdominal organs was performed: almost all ventral parts of the abdominal cavity with echo-dense walls 1.5-2.0 mm thick, the contents of the cavity are liquid with a significant amount of floating echo-dense suspension (Figure 5). A survey radiography of the abdominal organs was performed

(according to the severity of the condition in a horizontal position): a significant increase in the volume of the abdominal cavity with a high standing of the domes of the diaphragm, a small amount of air in the stomach and the initial sections of the intestine, multiple calcifications in the abdominal cavity (Figure 6).

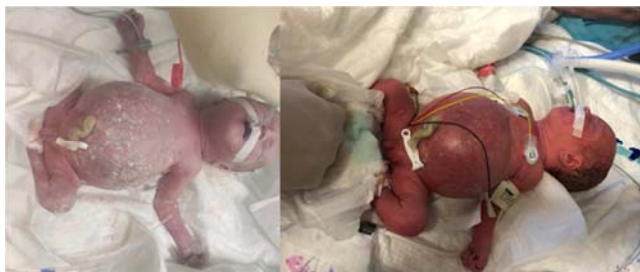

Figure 4. Appearance of a newborn G. at 1 minute after birth and 2 hours later (from left to right).

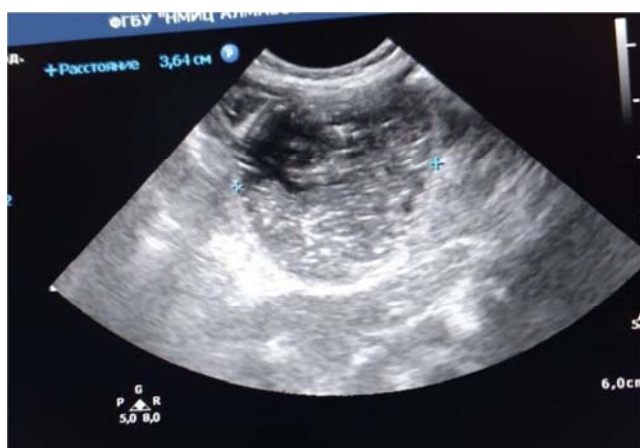

Figure 5. Ultrasound of the abdominal cavity after birth.

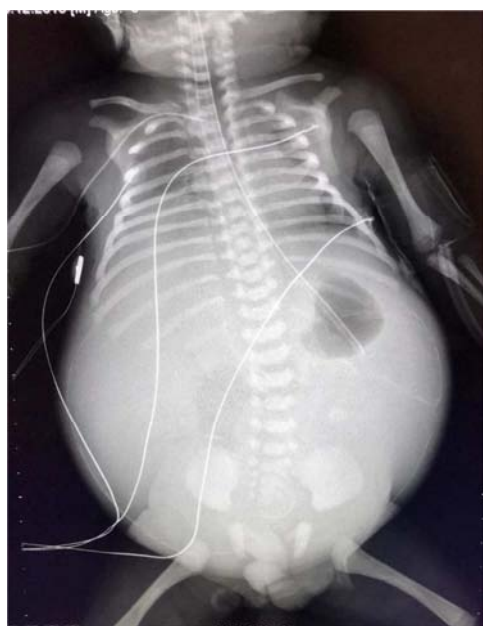

Figure 6. X-ray of the abdominal organs after birth.

The child was prepared for surgical treatment 3 hours after birth. The operation was carried out in the resuscitation and

intensive care unit due to the serious condition of the child (to exclude the stage of transportation to the operating room). The child was prepared for surgical treatment 3 hours after birth. The abdominal cavity was opened in layers with a simultaneous dissection of the anterior wall of the pseudocyst (Figure 7). Cyst contents - 450 ml of liquid contents with meconium. After the evacuation of the contents, the walls of the pseudocyst are visualized, occupying 3/4 of the abdominal cavity, adjacent to the lower surface of the liver, the right and left flanks of the abdomen, spreading to the small pelvis. In the right half, along the posterior surface of the pseudocyst, a section of the small intestine with perforation in the form of a labial fistula opens. The posterior wall of the pseudocyst was opened - loops of the small intestine were visualized, welded into a single conglomerate, all loops of the same diameter 0.6-0.7 cm, pink, shiny, peristaltic. The volvulus of the small intestine is determined for 8 cm, opening by perforation into the pseudocyst (Figure 8). Resection of 8 cm of the adductor small intestine carrying volvulus was performed. *It was estimated* that the adductor gut was about 40 cm long from Treitz's ligament, while total adhesiolysis was not performed. A double enterostomy with the removal of the stoma into the wound was formed (Figure 9). The histological conclusion: pseudocyst of the anterior abdominal wall; acute erosive and ulcerative enteritis; fibrinous-purulent peritonitis.

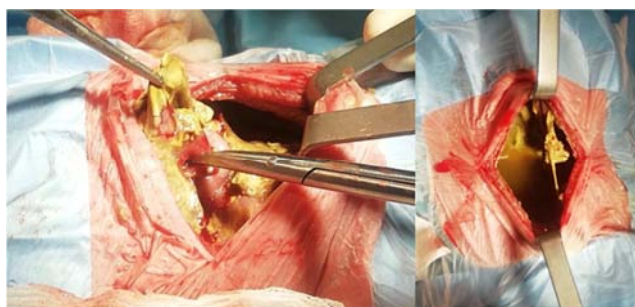


Figure 7. Opened abdominal pseudocyst.

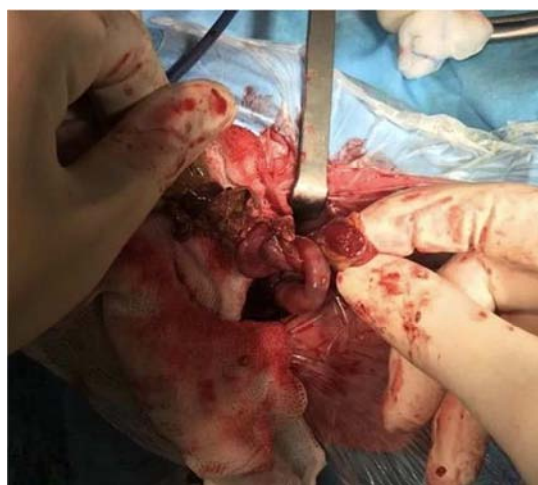

Figure 8. Volvulus of the atresized portion of the small intestine with perforation into the cyst cavity.

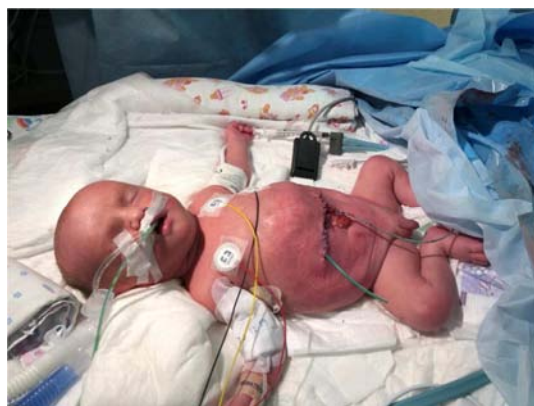

Figure 9. Appearance of the newborn G. immediately after surgery.

The postoperative period was without surgical complications, the child was in the intensive care unit. On the 4th postoperative day, he was extubated, on the 5th - without oxygen dependence. Nutrition was started from the 6th postoperative day in trophic volume with Alfara mixture with gradual expansion to 1/3 of the physiological volume through the horn. Partially enteral feeding was performed in the disconnected segment of the intestine.

In 3 weeks after the operation, the contrasting of the disconnected section of the intestine was performed - the intestine was freely passable, its diameter was very narrow, the gastrulation was preserved (Figure 10); enteral feeding was carried out into the disconnected section of the intestine. After 12 days, repeated contrasting of the disconnected section of the intestine was performed - the intestine was freely passable, the diameter of the intestine was satisfactory (see Figure 10).

Thus, the child is prepared for reconstructive surgery:

24.01.2020 - double enterostomy closure, entero-enteroanastomosis end-to-end.

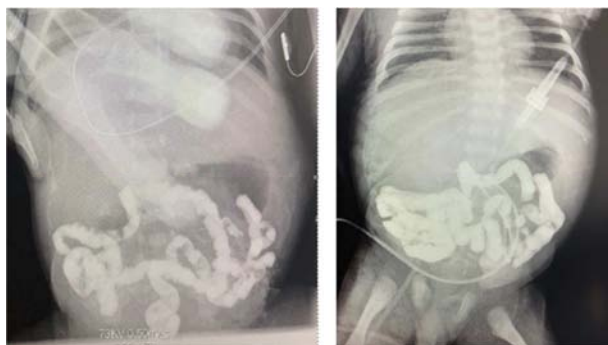

Figure 10. Contrasting of the disabled intestine on 01/08/2020 and 01/20/2020 (from left to right).

The postoperative period was uneventful. On the 5th postoperative day, he was transferred to the intensive care unit of the Department of Pediatric Surgery of Malformations. Enteral feeding was started from the 5th postoperative day, with a gradual expansion to full enteral feeding by the 12th day. The stitches were removed on the 8th postoperative day. The wound healed by primary intention.

The results of a molecular genetic study of the CFTR gene

for the presence of the most common mutations were not found (cystic fibrosis was excluded).

Discharged with recovery on 07.02.2020 at the age of 1.5 months in a satisfactory condition.

3. Case Study

With meconium peritonitis present, timely prenatal diagnosis is extremely important, which significantly improves the prognosis and allows prenatally to carry out measures aimed at stabilizing the condition of the fetus and the pregnant woman. In the given clinical case, a trans-amniotic puncture of the fetal abdominal cavity and amnioreduction were performed, which made it possible to reduce the degree of compression of the internal organs, which made it possible to avoid drainage of the abdominal cavity as the first stage of surgical treatment. Due to the appearance of ultrasound criteria of severity (meconium ascites, compression of the chest cavity of the fetus, dropsy and polyhydramnios), it became possible to predict the course of development of meconium peritonitis [11-13]. Prenatally, MP must be distinguished primarily from non-immune dropsy. Calcifications are considered a classic sign of MP, but they can also appear in organs that are not related to the gastrointestinal tract (calcifications of the liver, spleen), with cytomegalovirus infection, in the structure of some neoplasms. Meconium pseudocysts must also be differentiated with other fluid formations (megacystis, cysts of the ovary, urachus, mesentery, intestinal duplication, hematomas and presacral teratomas) [14, 15]. According to S. Nam et al. [16], MP diagnosed prenatally in 92.7% of patients. There is no consensus on the advisability of using other methods of diagnostics of MP (MRI, CT, etc.). Most authors [12, 13] believe that ultrasound is the main method of prenatal diagnosis of MP, and MRI and CT are indicated only if it is necessary to differentiate with other defects. Antenatal ultrasound allows not only to diagnose MP, but also to determine the timing and method of delivery. A child with MP should be born in a specialized perinatal center that has a highly specialized pediatric surgical service. The timing of delivery is determined by the prenatal consultation. Premature delivery is indicated with an increase in fetal hypoxia due to an increase in abdominal volume, according to ultrasound data [11, 16]. In this case, due to the progressive course of the MP, it was necessary to re-puncture the fetal abdominal cavity. The authors find this tactic safe and effective for decompression of the abdominal cavity. Also, if it is impossible to carry out unloading amniolaparocentesis prenatally, it is recommended to drain the cysts immediately after birth, and operate on children later, to stabilize the general condition [15-16]. In the given clinical case, a patient with ultrasound signs of low bowel obstruction in the fetus, dilated bowel loops, calcifications, ascites and polyhydramnios underwent intrauterine puncture of the abdominal cavity, which demonstrated the effectiveness of its prenatal and made it possible to perform the operation early after birth without the need for preliminary drainage of

the pseudocyst cavity and stabilization of the condition for the possibility of surgical treatment.

Our experience coincides with the opinion of the authors, and confirms that only a comprehensive approach of specialists to treatment both at the stage of intrauterine development and after the birth of a child ensures high survival, and the joint management of fetal and pediatric surgeons allows achieving the best outcomes.

4. Conclusions

1. If the fetus detects signs of myconium peritonitis, it is necessary to guide the patient in the conditions of the Perinatal Center of the 3rd level.
2. Joint supervision by specialists is recommended: neonatologists, fetal surgeons, pediatric surgeons, obstetricians-gynecologists.
3. In some cases, intrauterine intervention allows to prolong pregnancy and to carry out surgical treatment of MP at an earlier period after childbirth.

Conflict of Interests

The authors declare no conflict of interest.

Acknowledgements

The study had no sponsorship.

References

- [1] Ignatiev EM, Karavaeva SA, Kotin AN, et al. On the experience of surgical treatment of meconium peritonitis. Scientific Bulletin of BelSU. Series: Medicine. Pharmacy. Nauchnye vedomosti BelGU. Seriya: Medicina. Farmaciya. 2012; 123 (4). (in Russian).
- [2] Cerise E. J., Whitehead W. Meconium peritonitis. Am Surg. 1969; 35: 389.
- [3] Wang C. N., Chang S. D., Chao A. S., et al. Meconium peritonitis in determining neonatal outcome. Taiwan J ObstetGynecol. 2008; 47 (4): p. 391–6.
- [4] Nam, S. H., S. C. Kim, D. Kim, et al. Experience with meconium peritonitis. Journal of pediatric surgery. 2007; 42. 11: p. 1822-5.
- [5] Lorimer W. S. Jr, Ellis D. G. Meconium peritonitis. Surgery. 1966 Aug; 60 (2): p. 470-5. PMID: 5920370.
- [6] Ein SH, Shandling B, Reilly BJ, Stephens CA. Bowel perforation with nonoperative treatment of meconium ileus. J Pediatr Surg. 1987; 22 (2): 146-147. doi: 10.1016/s0022-3468(87)80434-7.
- [7] Nemilova T. K., Karavaeva S. A., Ignatiev E. M. Meconium peritonitis: modern interpretation, diagnosis, tactics, treatment. Bulletin of surgery named after I. I. Grekov Vestnik hirurgii imeni I. I. Grekova. 2012; 171 (4): 108-11. (in Russian).
- [8] Wang Y., Wu Y., Guan W., et al. Meconium peritonitis due to fetal appendiceal perforation: two case reports and a brief review of the literature. BMC Pediatr. 2018 May 11; 18 (1): 162. doi: 10.1186/s12887-018-1133- Review. ubMed PMID: 29751786; PubMed Central PMCID: PMC5948796.
- [9] Karavaeva SA, Ignatiev EM, Kotin AN, et al. Meconium peritonitis in children with duodenal atresia. Neonatology, surgery and perinatal medicine. Neonatologiya, hirurgiya i perinatal'naya medicina. 2012; 2 (4): 120-123. (in Russian).
- [10] McDuffie RS Jr, Bader T. Fetal meconium peritonitis after maternal hepatitis A. Am J Obstet Gynecol. 1999 Apr; 180 (4): 1031-2. doi: 10.1016/s0002-9378(99)70678-2. PMID: 10203675.
- [11] Shinmoto, H., Kuribayashi, S. MRI of fetal abdominal abnormalities. Abdom Imaging 28, 877–886 (2003). <https://doi.org/10.1007/s00261-003-0047-5>.
- [12] Gupta P, Sharma R, Kumar S, Gadodia A, Roy KK, Malhotra N, Sharma JB. Role of MRI in fetal abdominal cystic masses detected on prenatal sonography. Arch Gynecol Obstet. 2010 Mar; 281 (3): 519-26. doi: 10.1007/s00404-009-1190-1. Epub 2009 Aug 12. PMID: 19672611.
- [13] Zangheri G, Andreani M, Ciriello E, Urban G, Incerti M, Vergani P. Fetal intra-abdominal calcifications from meconium peritonitis: sonographic predictors of postnatal surgery. Prenat Diagn. 2007 Oct; 27 (10): 960-3. doi: 10.1002/pd.1812. PMID: 17654754.
- [14] Pelizzo G, Codrich D, Zennaro F, Dell'oste C, Maso G, D'Ottavio G, Schleef J. Prenatal detection of the cystic form of meconium peritonitis: no issues for delayed postnatal surgery. Pediatr Surg Int. 2008 Sep; 24 (9): 1061-5. doi: 10.1007/s00383-008-2194-9. Epub 2008 Jul 31. PMID: 18668257.
- [15] Nam S. H., Kim S. C., Kim D. Y. et al. Experience with meconium peritonitis. J. Pediatric Surgery. 2007 Nov; 42 (11): 1822-5, DOI: <https://doi.org/10.1016/j.jpedsurg.2007.07.006>.
- [16] Hibi M., Shimotake T., Iwai N. Combined esophageal and duodenal atresia complicated with meconium peritonitis. Pediatr. Surg. Int. 2003 Oct; 19 (7): 564-5 DOI: 10.1007/s00383-002-0946-5.